

# Surgical importance of variant hepatic blood vessels: a case report

*Importância cirúrgica de variações em vasos sanguíneos hepáticos:  
relato de caso*

Thejodhar Pulakunta,<sup>1</sup> Bhagath Kumar Potu,<sup>1</sup> Vasavi Rakesh Gorantla,<sup>2</sup>  
Venkata Ramana Vollala,<sup>3</sup> Jency Thomas<sup>2</sup>

### Abstract

This report describes a variation in blood vessels of the liver and abnormal entry of hepatic arteries into the liver found during routine dissection in an approximately 43-year-old male cadaver. An accessory hepatic artery arose from the superior mesenteric artery and entered the liver at the porta hepatis, whereas the proper hepatic artery was seen entering the left liver lobe at the fissure for ligamentum venosum. Clinical implications of such variation are discussed in the article.

**Keywords:** Hepatic artery, accessory hepatic artery, liver transplantation.

### Introduction

Various types of vascular anomalies are frequently found in human abdominal viscera in dissection laboratories and during radiological imaging. Literature describes incidence of “normal” hepatic arterial anatomy ranging between approximately 50-80% of individuals.<sup>1-7</sup> Patterns of arterial blood supply to the liver are variable. A number of hepatic artery variations are reported to exist.<sup>8</sup> A replaced hepatic artery is a substitute for a normal artery that is not present; an accessory hepatic artery is an artery that is additive to one that is normally present and with smaller diameter, but nonetheless is functionally essential and have a specific distribution in each case.<sup>8</sup> The surgeon has no possibility to decide whether an artery is replaced or accessory, although it is important to know that the aberrant artery may supply part of one liver lobe (accessory artery) or a whole liver lobe (replaced artery), because every ligation could lead to a segment or liver lobe necrosis.<sup>9,10</sup>

### Resumo

Este relato descreve uma variação nos vasos hepáticos e uma entrada anormal de artérias hepáticas no fígado, encontradas durante uma dissecação de rotina em um cadáver masculino de aproximadamente 43 anos. Uma artéria hepática acessória surgiu da artéria mesentérica superior e entrou no fígado no porta hepatis, ao passo que se constatou que a artéria hepática própria entrava no lobo hepático na fissura do ligamento venoso. Implicações clínicas desta variação são discutidas neste artigo.

**Palavras-chave:** Artéria hepática, artéria hepática acessória, transplante hepático.

We are reporting this case to create awareness in surgeons to take care and identify arterial variations before visceral resection.

### Case report

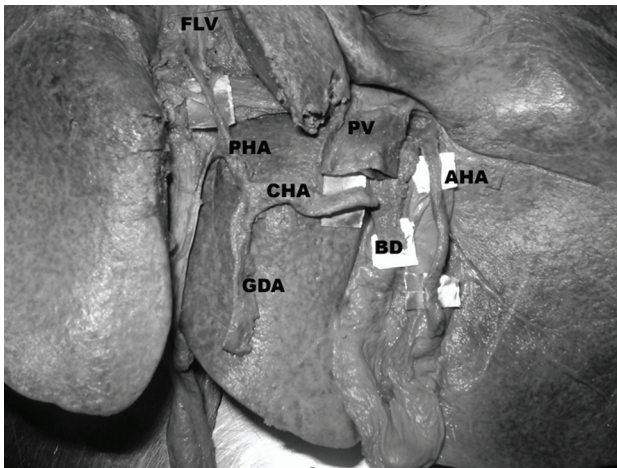
During routine dissection in the Department of Anatomy, Kasturba Medical College, Manipal, a 43-year-old male cadaver revealed the superior mesenteric artery (SMA) having its origin right next to the celiac trunk (CT). On further dissection, we noticed that the CT was giving rise to all three of its normal branches, which followed their usual course, except for the proper hepatic artery. Even the common hepatic artery (CHA) had its normal origin and course from the CT running towards the right side. It continued upwards as the proper hepatic, after giving off the gastroduodenal artery (GDA). It entered the liver at the fissure for ligamentum venosum (FLV) and gave two branches to the left lobe and one to the right lobe (Figure 1).

- 
1. Department of Anatomy, Centre for Basic Sciences, Kasturba Medical College, Manipal University, Manipal, Karnataka, India.
  2. Department of Anatomy, KMC International Centre, Manipal University, Manipal, Karnataka, India.
  3. Department of Anatomy, Melaka Manipal Medical College, Manipal University, Manipal, Karnataka, India.

Manuscript received Jul 06 2007, accepted for publication Jan 28 2008.

J Vasc Bras. 2008;7(1):84-86.

Copyright © 2008 by Sociedade Brasileira de Angiologia e de Cirurgia Vasculiar



AHA = accessory hepatic artery; BD = bile duct; CHA = common hepatic artery; FLV = fissure for ligamentum venosum; GDA = gastroduodenal artery; PHA = proper hepatic artery; PV = portal vein.

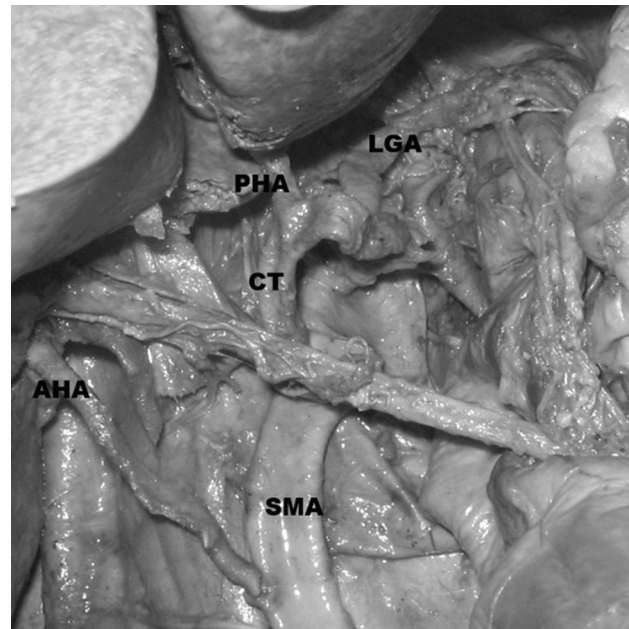
**Figure 1** - Proper hepatic artery entering the fissure for ligamentum venosum and accessory hepatic artery entering the porta hepatis

However, an accessory hepatic artery was seen arising from the SMA. This artery was arising from the convexity in the proximal 2 cm of the SMA (Figure 2). It was running obliquely upwards and to the right, lying anterior to the inferior vena cava (IVC). At the porta hepatis, it was lying to the right of the bile duct.

### Discussion

Knowing anomalous origin of hepatic arteries is important for successful hepatobiliary and liver transplant surgeries. A number of abnormalities occurring in hepatic artery anatomy are reported by various authors.<sup>8,11-14</sup> Abdullah et al. studied 932 cases of liver transplantation and reported that normal hepatic artery distribution was found in 635 cases (68.1%). Variations of hepatic artery were detected in 297 subjects (31.9%) and were divided into three groups, describing 48 (52%) CHA anomalies, 236 (25.3%) left hepatic artery (LHA) or right hepatic artery (RHA) anomalies, and 13 (1.4%) rare variations.<sup>1</sup>

Gruttadauria et al. studied 701 patients and encountered hepatic artery anomalies in 42%. In his study, the most common anomaly was a replaced/accessory RHA arising from the SMA (15%); they also reported one case



AHA = accessory hepatic artery; CT = celiac trunk; LGA = left gastric artery; PHA = proper hepatic artery; SMA = superior mesenteric artery.

**Figure 2** - Hepatic and accessory hepatic arteries arising from the celiac trunk and the superior mesenteric arteries, respectively

of a LHA arising from a proper hepatic artery with a RHA arising from a GDA.<sup>4</sup>

A study performed by Covey et al. on 600 digital subtraction angiographies of the hepatic arterial tree reported that 61.3% of patients had standard arterial anatomy. Approximately 15% of these individuals were found to have variant right hepatic arterial supplies, with accessory right hepatic arteries seen in 2.5% of patients. Of the accessory right hepatic arteries seen, 73% arose from the SMA, with one each arising from the left gastric artery, CT, right phrenic artery and GDA.<sup>2</sup>

Jones & Hardy also reported abnormalities in 43% of 180 cadaveric dissections, with 48% of these having multiple anomalies present. In 75% of cases the RHA arose from the proper hepatic artery, in 17% from the SMA and in 6% from the GDA.<sup>5</sup>

In the current study, the site of entry of the proper hepatic artery into the liver is at the FLV. To the best of

our knowledge, there are no articles in the literature commenting on the site of entry. The accessory RHA arising from the SMA is in accordance with previous studies.<sup>1,2,4,5,8</sup> Among the variations of accessory hepatic artery, this type is the most commonly found. Our greatest limitation was that we were unable to find out how much of the liver tissue is being supplied by each of these arteries as we do not have the infrastructure for such studies.

All these hepatic artery variations must be appropriately managed during split liver transplantation to ensure a complete vascular and biliary supply to both grafts.<sup>15</sup>

When questions arise during bench surgical preparation of the graft, assistance of an angiogram can be helpful to better understand variant anatomy before further dissection is carried out. Despite its apparent rarity, this variant aspect, as well as others, should be known by transplant surgeons.

#### Acknowledgements

We are grateful to Daphne Pereira, Binod Kumar Tamang, Vishal Kumar, and Soubhagya Ranjan Nayak for their valuable contributions during the revision of the article.

#### References

1. Abdullah SS, Mabrut JY, Garbit V, et al. [Anatomical variations of the hepatic artery: study of 932 cases in liver transplantation](#). Surg Radiol Anat. 2006;28:468-73.
2. Covey AM, Brody LA, Maluccio MA, Getrajdman GI, Brown KT. [Variant hepatic arterial anatomy revisited: digital subtraction angiography performed in 600 patients](#). Radiology. 2002;224:542-7.
3. De Santis M, Ariosi P, Calo GF, Romagnoli R. [Hepatic arterial vascular anatomy and its variants](#). Radiol Med (Torino). 2000;100:145-51.
4. Gruttadauria S, Foglieni CS, Doria C, Luca A, Lauro A, Marino IR. [The hepatic artery in liver transplantation and surgery: vascular anomalies in 701 cases](#). Clin Transplant. 2001;15:359-63.
5. Jones RM, Hardy KJ. [The hepatic artery: a reminder of surgical anatomy](#). J R Coll Surg Edinb. 2001;46:168-70.
6. Peschard F, El Hajjam M, Malafosse R, et al. [A common hepatic artery passing in front of the portal vein](#). Surg Radiol Anat. 2006;28:202-5.
7. Volpe CM, Peterson S, Hoover EL, Doerr RJ. [Justification for visceral angiography prior to pancreaticoduodenectomy](#). Am Surg. 1998;64:758-61.
8. Michels NA. Blood supply and anatomy of the upper abdominal organs. Philadelphia: JB Lippincott; 1955.
9. Arnold MM, Kreel L, Lo YF, Law H. [Are the hepatic arteries "end arteries"?](#) Invest Radiol. 1991;26:337-42.
10. Weiglein AH. [Variations and topography of the arteries in the lesser omentum in humans](#). Clin Anat. 1996;9:143-50.
11. Haller A. Icones Anatomicae in quibus praecipuae partes corporis humani delineate proponuntur et arteriarum potissimum historia continetur. Gottingen. Vandenhoeck. 1756:VIII 270.
12. Tiedemann F. Tabularum arteriarum corporis humani. In: Koepfers, Karlsruhe, Müller CF, eds. Abbildungen der Pulsadern des menschlichen; 1822. p. 1-250.
13. Adachi B. Arterien system der Japaner. Kyoto: Kerkyusha; 1928. Band II 46-60.
14. Flint ER. Abnormalities of the right hepatic, cystic and gastro duodenal arteries and of the bile ducts. Brit J Surg. 1923;10:509-19.
15. Streitparth F, Pech M, Figolska S, et al. [Living related liver transplantation: preoperative magnetic resonance imaging for assessment of hepatic vasculature of donor candidates](#). Acta Radiol. 2007;48:20-6.

---

#### Correspondence:

Bhagath Kumar Potu  
 Department of Anatomy, Center for Basic Sciences  
 Kasturba Medical College  
 576104 - Manipal, Karnataka - India  
 Tel.: +91 820-2922327  
 E-mail: potu\_kumar2000@yahoo.co.in