

Endovascular treatment of endotension with dacron stent graft reinforcement and femorofemoral crossover bypass - therapeutic challenge

Tratamento endovascular da endotensão com endoprótese de dácron e derivação femoro-femoral cruzada - desafio terapêutico

Edwaldo Edner Joviliano¹, Marcelo Bellini Dalio², José Geraldo Ciscato Junior², Nei Rodrigues Alves Dezotti², Takachi Moriya¹, Carlos Eli Piccinato³

Keywords: Aortic aneurysm, blood vessel prosthesis, vascular surgical procedures endotension.

Palavras-chave: Aneurisma aórtico, prótese vascular, procedimentos cirúrgicos vasculares, endotensão.

Part I - Clinical case

A 54 year-old man with an asymptomatic 5.9 cm AAA was treated with an Excluder® 26 mm/14.5 mm/16 cm endoprosthesis (Gore, USA). Initial aortic morphology showed a proximal neck of 2.0 cm of extension by 23 mm of diameter. The common iliac arteries measured 13 mm in right diameter and 12 mm in left diameter. No endoleak was detected immediately after the procedure.

One month after the procedure, computed tomography (CT) scan showed maintenance of aneurysmal diameters without evidence of endoleak (Figure 1). After one year, follow-up duplex ultrasound and CT scan showed no endoleak, but a small growth of the aneurysmal sac to 6.2 cm was observed (Figure 2). Aortography with selective visceral and hypogastric arteries showed no endoleak (Figure 3). We decided to observe the outcome of the condition with a second CT scan within six months. The patient only returned after one year, when CT scan found the aneurysmal diameter had increased to 7.5 cm, but without evidence of endoleak. The case was interpreted as endotension, and intervention was considered. Since the patient presented class II heart failure, poorly controlled cardiac arrhythmia and a previous

left pneumonectomy for a neoplasm, an endovascular approach was chosen.

Part II - What was done?

Endovascular intervention was performed using a right aorto-mono-iliac Zenith® endoprosthesis (Cook, USA) 28 mm/125 mm with and extension 12 mm/88 mm deployed inside the previous one and an occluder 14 mm/20 mm for the left iliac artery. Pre-procedure aortography showed no evidence of endoleak. After endograft deployment, a femoro-femoral crossover left-right bypass graft with 8 mm PTFE was carried out. No complication was noted and the patient was discharged after two days.

After six months, a new CT scan showed an aneurysmal diameter of 6.5 cm, i.e., a reduction of 1 cm compared with the pre-intervention exam (Figure 4).

CT scan studies were all performed using a 16-slice helical scanner. All series, including noncontrast images, were obtained at 5.0 mm thickness. Arterial phase images were obtained at 3.0 mm thickness and later reconstructed at 1.5 mm thickness.

The mechanism of persistent sac pressurization without endoleak has yet to be explained. It seems to be the result of

¹ Professor Associado, Divisão de Cirurgia Vascular e Endovascular, Departamento de Cirurgia e Anatomia, Faculdade de Medicina de Ribeirão Preto (FMRP), Universidade de São Paulo (USP), Ribeirão Preto, SP.

² Médico Assistente, Divisão de Cirurgia Vascular e Endovascular, Departamento de Cirurgia e Anatomia, FMRP, USP, Ribeirão Preto, SP.

³ Professor Titular, Divisão de Cirurgia Vascular e Endovascular, Departamento de Cirurgia e Anatomia, FMRP, USP, Ribeirão Preto, SP.

No conflicts of interest declared concerning the publication of this article.

Manuscript received Oct 27 2009, accepted for publication Mar 23 2010.

J Vasc Bras. 2010;9(2):81-84.

pressure transmission and fluid accumulation facilitated by increased graft porosity, like that observed in the original PTFE from the Gore Excluder® device.⁸ Kotke-Marchant et al.⁹ demonstrated that graft fabrics could activate leukocytes and the complement system to varying degrees: PTFE exhibited minimal complement activation and leukocyte adhesion, but dacron strongly activated both complement and leukocytes. Trocciola et al.,¹⁰ reported transudation of serum components in an animal model of aortic aneurysm that had been excluded with an expanded PTFE stent graft. By comparison, aneurysm exclusion with a dacron stent graft resulted in significantly less pressure transmission in the aneurysm sac and demonstrated greater thrombus organization. Gore Excluder® has been shown to have a lower incidence of aneurysm sac shrinkage. Melissano et al showed an incidence of 37% for Excluder®.⁸ In 2004, Gore

altered the design of the Excluder® with the aim of decreasing porosity; the effect of this change on reducing the incidence of endotension is still under investigation. Recent work has showed that sac behavior after EVAR with this newer low-permeability Excluder® endoprosthesis is significantly improved compared with the previous one. This new design may be a solution for the endotension problem.¹¹

Treatment for patients with endotension remains controversial. Mennander et al.¹² proposed a nonoperative approach for endotension. In their study, three patients presented ruptured aneurysm during the follow-up, without associated hemorrhage, confirming a continuous increase in sac size and aneurysm wall tension in the presence of an effective endograft seal. Evidently, sac enlargement is not always associated with blood flow inside the sac, and continuous filtration of transudative material through the

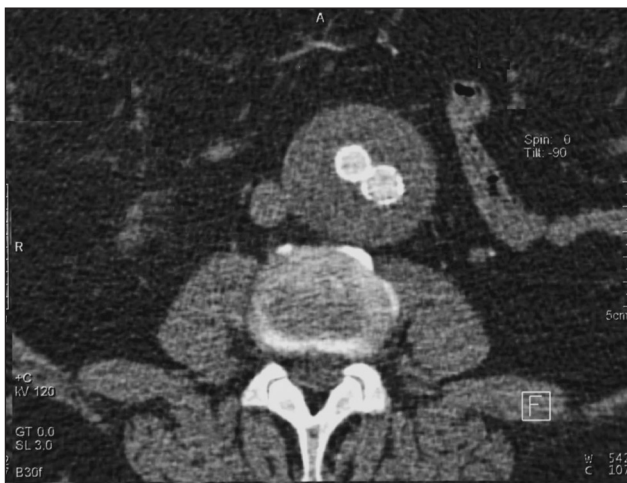

Figure 1 - Computed tomography angiography at one month without evidence of endoleak

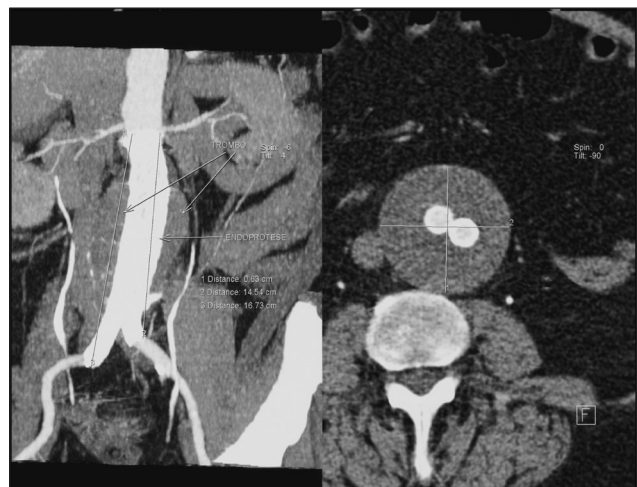


Figure 2 - Computed tomography angiography showing increase in aneurysm sac diameter

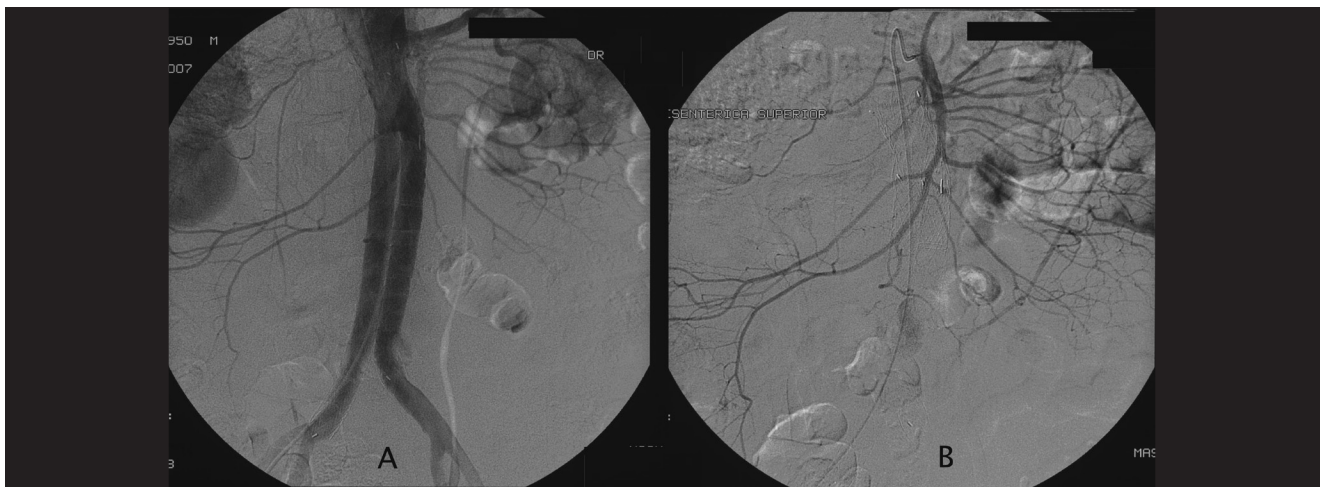


Figure 3 - A) Aortography and B) selective angiography showing no endoleak

graft may result in sac rupture. The fact that the aneurysmal sac can burst because of endotension and the poorly understood consequences of this rupture make conservative treatment fail as a better choice for such patients. A recent consensus recommended that aneurysmal sac enlargement associated with endotension needs to be treated.¹³ Open surgery can be a definitive solution, but it can be difficult to recommend it because of the surgical risk of most of these patients.

Different authors have described techniques without aortic cross clamping and other less invasive options. Risberg et al.⁵ reported that puncture, fenestration or resection of the sac did not seem to be adequate. Mory et al.¹⁴ suggested an open surgical approach based on decompression and fenestration of the aneurysm sac, proximal aortic neck banding, and transmural endograft fixation with good results in three cases. However, this technique did not obviate major laparotomy and did not exclude the endograft that retained its porosity.

Various authors have proposed treatment with endograft relining with satisfactory results. Goodney & Fillinger¹⁵ reported nine cases using another Excluder® device with a mean follow-up of 16 months, in which mean diameter decreased 2.0 mm/year and mean sac volume decreased 2.6% per year. They argued for a selective strategy in three ways: reline limbs only; reline limbs only and advance the bifurcation; and reline with aortic cuff and limbs. It depends on the parts in contact with the sac. Kougiass et al.⁶ also reported cases of endograft relining with another Excluder® component. The use of aortic cuffs and limbs clearly does not totally eliminate contact between the relatively porous PTFE graft and flowing blood. The authors believe that the dynamic process of transudation and resorption would be tipped in favor of resorption. Sac expansion appeared to be arrested by relining the high-permeability device with low-permeability Excluder® endoprosthesis components. Conversely, the nature of the original expansion pattern makes it difficult to declare that the relining procedure with another PTFE is a definitive solution for endotension.

In our report we did not detect any previous endoleak and the patient was not submitted to any intervention other than aortouniiliac endograft with femorofemoral crossover bypass. We describe a technique with total exclusion of the previous components using a graft with known low permeability, such as dacron from Zenith® graft. Smith et al. showed a rapid sac diameter decrease of 41 mm in six months.⁷ In our case, the sac decreased by 10 mm in six months. This case reports a valuable minimally invasive option for patients with endotension

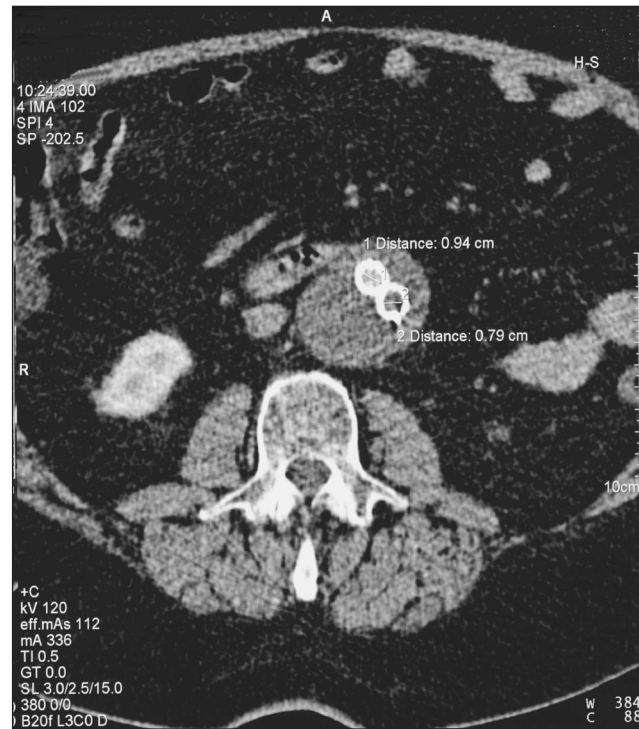


Figure 4 - Computed tomography angiography at six months after new endovascular procedure showing aneurysm sac shrinkage

and an alternative to open surgical conversion or relining with another PTFE graft.

In conclusion, an increase in aneurysmal sac diameter by endotension after EVAR is an indication for intervention. For patients with advanced age or poor clinical conditions, a minimally invasive technique may be more suitable than open surgical conversion. Endovascular treatment of endotension with dacron stent graft seems to be a safe and efficient alternative to relining with another PTFE stent graft.

References

1. EVAR trial participants. Endovascular aneurysm repair versus open repair in patients with abdominal aortic aneurysm (EVAR trial 1): randomized controlled trial. *Lancet*. 2005;365:2179-86.
2. EVAR trial participants. Endovascular aneurysm repair and outcome in patients unfit for open repair of abdominal aortic aneurysm (EVAR trial 2): randomized controlled trial. *Lancet*. 2005;365:2187-92.
3. Gilling-Smith G, Brennan J, Harris P, Bakran A, Gould D, McWilliams R. Endotension after endovascular aneurysm repair: definition, classification, and strategies for surveillance and intervention. *J Endovascular Surg*. 1999;6:305-7.
4. Fillinger M. Three-dimensional analysis of enlarging aneurysms after endovascular abdominal aortic aneurysm repair in the Gore Excluder Pivotal clinical trial. *J Vasc Surg*. 2006;43:888-95.

5. Risberg B, Delle M, Lönn L, Syk I. Management of aneurysm sac hygroma. *J Endovasc Ther.* 2004;11:191-5.
6. Kougias P, Lin PH, Dardik A, Lee WA, El Sayed HF, Zhou W. Successful treatment of endotension and aneurysm sac enlargement with endovascular stent graft reinforcement. *J Vasc Surg.* 2007;46:124-7.
7. Smith ST, Clagett GP, Arko FR. Endovascular conversion with femoro-femoral bypass as a treatment of endotension and aneurysm sac enlargement. *J Vasc Surg.* 2007;45:395-8.
8. Melissano G, Bertoglio L, Esposito G, Civilini E, Setacci f, Chiesa R. Midterm clinical success and behavior of the aneurysm sac after endovascular AAA repair with the Excluder graft. *J Vasc Surg.* 2005;42:1052-7.
9. Kottke-Marchant K, Anderson JM, Miller KM, Marchant RE, Lazarus H. Vascular graft associated complement activation and leukocyte adhesion in an artificial circulation. *J Biomed Mater Res.* 1987;21:379-97.
10. Trocciola SM, Dayal R, Chaer RA, et al. The development of endotension is associated with increased transmission of pressure serous components in porous expanded polytetrafluoroethylene stent-grafts: characterization using a canine model. *J Vasc Surg.* 2006;43:109-16.
11. Tanski W 3rd, Fillinger M. Outcomes of original and low-permeability Gore Excluder endoprosthesis for endovascular abdominal aortic aneurysm repair. *J Vasc Surg.* 2007;45:243-9.
12. Mennander A, Pimenoff G, Heikkinen M, Partio T, zeitlin R, Salenius JP. Nonoperative approach to endotension. *J Vasc Surg.* 2005;42:194-9.
13. Veith FJ, Baum RA, Ohki T, et al. Nature and significance of endoleaks and endotension: summary of opinions expressed at an international conference. *J Vasc Surg.* 2002;35:1029-35.
14. Mory M, Allenberg JR, Schumacher H, von Tengg-Kobligk H, Böckler D. Open decompression, proximal banding, and aneurysm sac fenestration as an alternative to conversion in the management of endotension after EVAR. *J Endovasc Ther.* 2008;15:449-52.
15. Goodney PP, Fillinger MF. The effect of endograft relining on sac expansion after endovascular aneurysm repair with the original-permeability Gore Excluder abdominal aortic aneurysm endoprosthesis. *J Vasc Surg.* 2007;45:686-93.

Correspondence:

Marcelo Bellini Dalio
 Departamento de Cirurgia e Anatomia, FMRP, USP
 Av. Bandeirantes, 3900, 90 andar,
 CEP 14048-900 – Ribeirão Preto, SP, Brazil
 Tel.: +55 16 3602.2406
 Fax: +55 16 3633.0836
 E-mail: mbdalio@gmail.com

Author contributions:

Conception and design: EEJ
 Analysis and interpretation: EEJ, MBD
 Data collection: JGCJ
 Writing the article: MBD, EEJ,
 Critical revision of the article: CEP, TM, NRAD
 Final approval of the article*: MBD
 Statistical analysis: N/A
 Overall responsibility: MBD
 Obtained funding: N/A

* All authors have read and approved the final version of the article submitted to J Vasc Bras.