

Fracture of the acromion associated with arterial lesion: case report

Fratura do acrômio associada a lesão arterial: relato de caso

Marcos Rassi Fernandes, Rui José Fernandes*

Abstract

Fracture of the acromion and arterial injury are a rare association. The clinical picture is characterized by shoulder pain, functional disability and swelling of the affected limb with decreased distal pulse and temperature. Radiography of the shoulder and arteriography define the diagnosis and assist in postoperative follow-up. The authors report a rare case of fracture of the acromion associated with injury of the ipsilateral ulnar artery and describe its treatment, as well as pre- and postoperative evaluations.

Keywords: Acromial lesions, bone fracture surgery, acromion radiography, acromion surgery, internal fixation of adult fractures.

Resumo

A fratura do acrômio com lesão arterial é uma associação rara. O quadro clínico caracteriza-se por dor no ombro, incapacidade funcional e edema do membro acometido, com pulso e temperatura distais diminuídos. A radiografia do ombro e a arteriografia definem o diagnóstico e auxiliam na evolução pós-operatória. Os autores relatam um caso raro de fratura da base do acrômio associada a lesão da artéria ulnar ipsilateral, seu tratamento, bem como a avaliação pré e pós-operatória.

Palavras-chave: Lesões do acrômio, cirurgia de fraturas ósseas, acrômio, radiografia do acrômio, cirurgia do acrômio, fixação interna de fraturas de adultos.

Introduction

The acromion (AC) is a strong bone that functions as a shield, protecting the structures of the subacromial region. It absorbs and dissipates the forces applied to the shoulder region;¹ however, high energy force may produce fractures, as well as other severe lesions. Therefore, diagnosis may not be immediately performed due to the necessity of assessing associated lesions.²

Acromion fracture is rare and accounts for only 9% of scapular fractures, which correspond to 1% of all the fractures.³ It may result from a direct force applied to the upper region of the AC, or a deviation or superior dislocation of the humeral head, which may also bring about a severe disruption of the rotator cuff.⁴

Fractures frequently present a minimal deviation and do not require surgical treatment. It is important to distinguish them from the *os acromiale*,¹⁻³ which is the failure of the AC's

ossification centers' fusion. In the case of a deviated fracture, association with brachial plexus lesion should be considered.⁵

Most AC fractures are concomitant with fractures of the acromion,⁶ clavicle,⁷ scapular neck or body,⁸ acromioclavicular dislocation⁹ or glenohumeral dislocation,³ but the neurovascular exam in high-magnitude trauma is always important.

This case report discusses a fracture of the AC's basis associated with ipsilateral ulnar artery lesion, its treatment and evolution, drawing attention to possible associations between these two lesions. The study was approved by the Research Ethics Committee of Hospital Geral de Goiânia.

Case report

A 21-year-old male patient presented with pain in the left shoulder, superior and posterior region, after a skate accident. He was then admitted in another service, where he

was anesthetized to 'put the shoulder right.' He came to the session with simple shoulder radiographs. The mother also reported a decrease in temperature in the patient's hand. At physical exam, he presented pain at palpation of the AC's posterior region, a significant swelling in all the left upper limb (LUL) and hematoma in the medial surface of the arm. The LUL had no functional ability, associated with filiform radial pulse and hand temperature decreased. No neurological deficit was observed. Simple shoulder radiographs showed fracture of the AC's basis with inferior and medial deviation (Figure 1). The patient was referred to the angiology division for an emergency evaluation. A color Doppler exam, with linear transducer of LUL's deep vases, was performed. No signs suggesting acute deep venous thrombosis were discovered. Radial artery was patent, with triphasic flow, while distal ulnar artery had inverted and reduced flow, with a short occluded segment in proximal forearm. Afterwards, a digital angiography was performed on the

LUL, assessing the following aspects: patent subclavian artery, patent brachial artery (Figure 2), patent radial artery, ulnar artery occluded soon after its origin with retrograde refilling (Figure 3), patent superficial palmar arch, and partially opacified deep palmar arch.

Vascular team chose to treat the arterial occlusion with acetylsalicylic acid (100 mg) and observation. Three days after first consultation, an ultrasonography was performed on the left shoulder, and the diagnosis evidenced the presence of diffuse subcutaneous swelling of shoulder and proximal arm; however, no lesion was observed in the rotator cuff. The patient was then discharged for surgical treatment of the AC fracture 10 days after trauma.

With an incision of approximately 8 cm in the superior surface of the shoulder, following the Langer skin lines and fracture after reduction, fixation was performed with two parallel Steinman wires, 2.5 mm, with threaded tips, posterior to anterior (Figure 4). The patient remained motionless

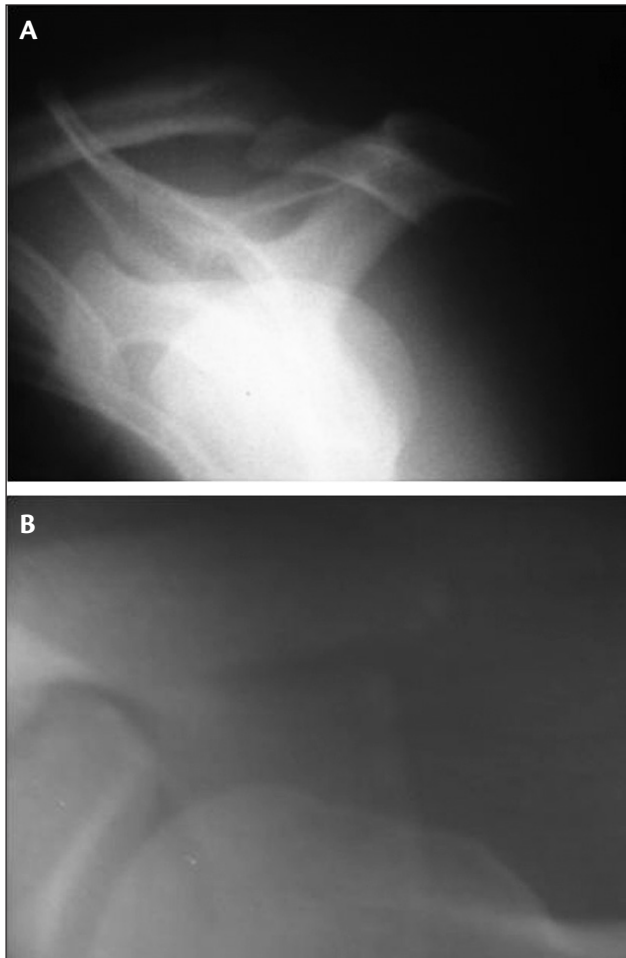


Figure 1 – A) Acromion fracture. Scapular profile evidencing a fracture with inferior deviation; B) axillary profile with medial deviation

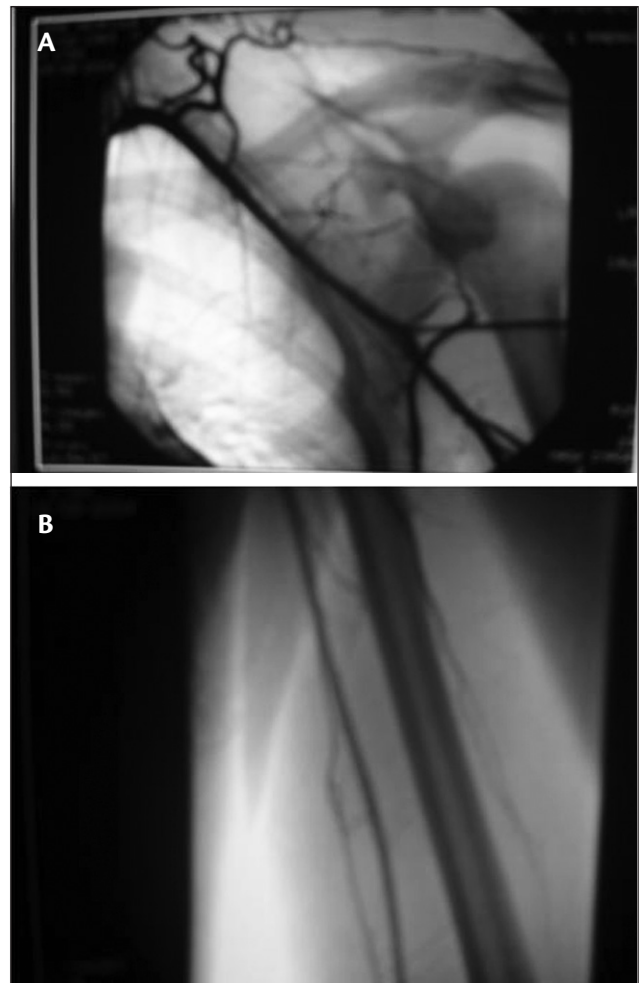


Figure 2 – Patent arteries A) subclavian and B) brachial

during 21 days. After that, passive and pendular exercises were resumed. The bolts were removed 6 weeks from postoperative, with the fracture consolidated (Figure 5). At 3 month's follow-up, the patient did not present shoulder pain, his movements had been recovered and the LUL had no edema, with normal pulse and temperature.

Discussion

The scapula plays an important role in the functioning of the arm. It is congruent with the rib cage and stabilizes the superior extremity against the thorax, in addition to joining the appendicular to the axial skeleton through the glenoid, clavicle and sternoclavicular and acromioclavicular articulations.^{1,2}

The low incidence of scapular fractures is due to its great mobility and position between muscle layers. A significant trauma is necessary to fracture this bone.^{2,3} Associated

lesions are common, therefore fractures are usually diagnosed late. Fischer et al.⁵ observed that 57% of patients with scapular fracture presented lesion of the brachial plexus and arterial lesion of the ipsilateral extremity. Armstrong and Vanderspuy¹⁰ reported that associated lesions are responsible for 10% of deaths in patients with scapular fracture.

Studies on acromion fractures are rare, and most of them comprise case reports. Mcgahan & Rab¹¹ reported a case of acromion fracture associated with acromioclavicular dislocation and axillary nerve lesion. Weber et al.¹² also reported a deviated and isolated acromion fracture, which reduced the subacromial space. Surgical treatment was necessary, evidencing that all fractures are combined, as demonstrated by Goodrich et al.³ and Goss.⁶

Mcgahan & Rab¹³ evidenced that traumas of the acromioclavicular articulation or acromion present a high incidence of peripheral nerves lesions, demanding

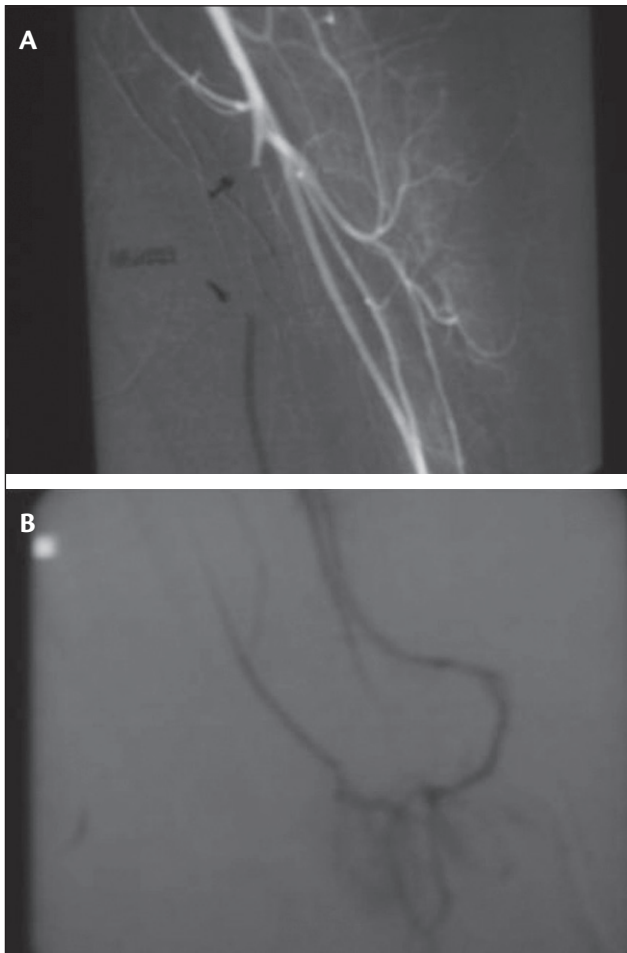


Figure 3 - A) Ulnar artery occluded soon after its origin; B) retrograde refilling



Figure 4 – Fixed fracture with two Steinmann 2.5 mm wires

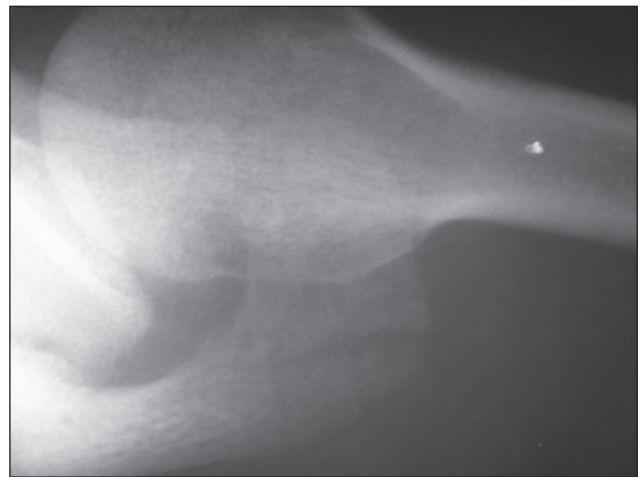


Figure 5 – Consolidated acromion fracture

a great deal of attention at the performance of neurological exams in these patients. Baldwin et al.,¹⁴ in a recent study, concluded that lesions of the upper limb, thorax and pelvic ring are frequently associated in patients with scapular fracture, due to the frequency of high-energy traumas in these cases.

Radiographic evaluation should always be the first to be performed, and the axillary side is the best incidence for the diagnosis. Computed tomography sometimes is necessary for assessing the fracture deviation and studying other associated bone lesions.^{2,4} Magnetic resonance and ultrasonography are helpful in assessing the soft parts of the shoulder region.² In this case report, a simple radiograph was sufficient for fracture diagnosis. Ultrasonography did not evidence lesion of the rotator cuff.

Kuhn et al.⁸ have proposed a classification of acromion fractures to indicate those in which surgical intervention would be necessary. Minimally deviated type I fractures and deviated type II fractures with no reduction of subacromial space would require non-surgical treatment. In deviated type III lesions with space reduction surgery is indicated to prevent secondary impact.

Literature on the association of acromion fracture with arterial lesion of any topography is very scarce. Few studies show this concomitance, although some represent correlations with all the types of scapular fractures, such as Fischer et al.,⁵ who evidence an 11% incidence of arterial lesion, and Stein et al.,¹⁵ who reported the case of a closed fracture of the scapula neck with axillary artery lesion.

This case report showing a closed fracture of the acromion associated with a lesion of the ulnar artery is, as far as our knowledge is concerned, the first to be described in literature showing exams, treatment and evolution. The most likely mechanism was an upper limb indirect trauma, with the elbow slightly flexed and the fist dorsiflexed due to the presence of an arterial lesion of the distal forearm to the shoulder fracture (AC), despite the absence of rotator cuff lesion. Therefore, arterial lesion did not occur due to a fracture deviation, which would happen if the lesion was more proximal. High-energy trauma should be the first parameter for considering the possibility of an association between these lesions. Surgical treatment, since it is a deviated fracture with subacromial space reduction, was correctly indicated, with good evolution, no pain and no movement restriction. Thus, a possible pseudarthrosis or vicious consolidation was avoided. The option of performing an artery occlusion with clinical treatment was due to the good distal perfusion through radial artery,

with a good filling of the deep palmar arch and retrograde refilling of ulnar artery.

The presence of an acromion fracture should always alert the physician assisting the patient, because severe lesions may be associated. A complete neurovascular exam is important. Therefore, surgical treatment of the deviated acromion fracture seems to be the best option when subacromial space is reduced. Associated arterial lesions should always be remembered.

References

1. De Palma AF. Fractura del acromion. In: De Palma AF, editor. *Cirurgia del ombro*. Philadelphia: Lippincott; 1985. pp. 484-5.
2. Butters KP. Fractures and dislocations of the scapula. In: Rockwood CA, Green DP, Bucholz RW, editors. *Fractures in adults*. Philadelphia: Lippincott; 1984. pp. 990-1019.
3. Goodrich JA, Crosland E, Pye J. Acromion fracture associated with posterior shoulder dislocation. *J Orthop Trauma*. 1998;12:521-3.
4. Getz C, Deutsch A, Williams Junior GR. Scapular and glenoid fractures. In: Warner JJP, Iannotti JP, Flatow EL, editors. *Complex and revision problems in shoulder surgery*. Philadelphia: Lippincott; 2005. pp. 378-80.
5. Fischer RP, Flynn TC, Miller PW, Thompson DA. Scapular fractures and associated major ipsilateral upper torso injuries. *Curr Concepts Trauma Care*. 1985;1:14-6.
6. Goss TP. The scapula: coracoid, acromial and avulsion fractures. *Am J Orthop (Belle Mead NJ)*. 1996;25:106-15.
7. Ogawa K, Naniwa T. Fractures of the acromion and the lateral scapular spine. *J Shoulder Elbow Surg*. 1997;6:544-8.
8. Kuhn JE, Blasier RB, Carpenter JE. Fractures of the acromion process: a proposed classification system. *J Orthop Trauma*. 1994;8:6-13.
9. Kurdy NM, Shah SV. Fracture of the acromion associated with acromioclavicular dislocation. *Injury*. 1995;26:636-7.
10. Armstrong CP, Van der Spuy J. The fractured scapula: importance in management based on a series of 62 patients. *Injury*. 1984;15:324-9.
11. Mcgahan JP, Rab GT. Fracture of the acromion associated with an axillary nerve deficit: a case report and review of the literature. *Clin Orthop Relat Res*. 1980;147:216-8.
12. Weber D, Sadri H, Hoffmeyer P. Isolated fracture of the posterior angle of the acromion: a case report. *J Shoulder Elbow Surgery*. 2000;9:534-5.
13. Mcgahan JP, Rab GT. Fractures of the scapula. *J Trauma*. 1980;20:880-3.
14. Baldwin KD, Ohman-Strickland P, Mehta S, Hume E. Scapula fractures: a marker for concomitant injury? A retrospective review of data in the National Trauma Database. *J Trauma*. 2008;65:430-5.
15. Stein RE, Bono J, Korn J, Wolff WI. Axillary artery injury in closed fracture of the neck of the scapula: a case report. *J Trauma*. 1971;11:528-31

Correspondence:

Marcos Rassi Fernandes
Av. Azaléias, Qd. 10 Lt. 20, Residencial Jardins Viena
CEP 74935-187 – Aparecida de Goiânia, GO
Tel.: +55 (62) 3523.1247, +55 (61) 9602.7575
E-mail: marcosombro@ig.com.br

Author contributions:

RConception and design: MRF

Analysis and interpretation: MRF, RF

Data collection: MRF

Writing the article: MRF

Critical revision of the article: MRF, RF

Final approval of the article:* MRF, RF

Statistic analysis: N/A

Overall responsibility: MRF

Obtained Funding: N/A

* All the authors have read and approved the final version of the article submitted to J Vasc Bras.