

Hydrothorax due to parenteral nutrition – a case report

Hidrotórax secundário à nutrição parenteral – relato de caso

José Henrique Silvah¹, Cristiane Maria Mártires Lima¹, Francisco Abaeté das Chagas-Neto², Guilherme Teixeira Araújo¹, Fernando Bahdur Chueire³, Selma Freire de Carvalho Cunha⁴, Júlio Sérgio Marchini⁵

Abstract

Hydrothorax due to parenteral nutrition infusion is a rare, although increasingly common event. This report shows a short bowel patient who developed hemodynamic instability and respiratory failure few hours after parenteral nutrition infusion's start. We also emphasize the maneuvers to avoid and treat such complication.

Keywords: hydrothorax; parenteral nutrition; short bowel syndrome.

Resumo

Hidrotórax secundário à infusão de nutrição parenteral é uma condição rara, embora se apresente cada vez mais comum. Neste relato de caso, uma paciente com síndrome do intestino curto desenvolveu instabilidade hemodinâmica e insuficiência respiratória algumas horas após o início da infusão de nutrição parenteral. Ressaltamos também as manobras para evitar e tratar tal complicação.

Palavras-chave: hidrotórax; nutrição parenteral; síndrome do intestino curto.

Introduction

Central vein catheterization for the administration of medications, chemotherapy drugs, hemoderivatives and parenteral nutrition is a routine procedure in hospitals, but it is not free of complications¹. We report the case of a patient who developed hydrothorax after insertion of a long-term central venous catheter (Port-a-Cath[®]) for total parenteral nutrition (TPN).

Case report

A 42-year-old female patient was admitted to the Nutrology Service of the *Hospital das Clínicas de Ribeirão Preto* in April, 2009, with short bowel syndrome (small bowel length of less than 15 cm) secondary to vascular pedicle torsion, plus a history of two previous abdominal operations.. She had been submitted to jejunioileal enterectomy from 15

cm distal to the ligament of Treitz to the terminal ileum, and to a gastrojejunal bypass, similar to a Roux-en-Y anastomosis.

Total parenteral nutrition (TPN) was administered through central venous catheter inserted by the Seldinger technique. Twenty days later, a Port-a-Cath[®] catheter was placed through the right internal jugular vein for long-term parenteral nutrition. Adequate positioning of the catheter tip and blood flow were confirmed by fluoroscopy. The short-term catheter was removed. Nineteen days later, the Port-a-Cath[®] device was punctured with a Huber needle (special needle, designed by Huber in 1946, that produces a non-coring puncture in the reservoir diaphragm), in order to start TPN infusion¹. Aspiration of blood through the catheter was not performed. On the first day of TPN, the patient complained of intense thoracic pain, tachypnea, tachycardia, abdominal pain referred to the right shoulder, decreased breath sounds in the right side and hemodynamic instability.

Study carried out at Hospital das Clínicas, Faculdade de Medicina de Ribeirão Preto, Universidade de São Paulo (USP) – Ribeirão Preto (SP), Brazil.

¹Resident of the Department of Internal Medicine and Nutrology at Faculdade de Medicina de Ribeirão Preto of USP – Ribeirão Preto (SP), Brazil.

²Resident of the Department of Internal Medicine and Radiology at Faculdade de Medicina de Ribeirão Preto of USP – Ribeirão Preto (SP), Brazil.

³Assistant Physician of Internal Medicine and Nutrology at Faculdade de Medicina de Ribeirão Preto of USP – Ribeirão Preto (SP), Brazil.

⁴PhD; Professor of Internal Medicine and Nutrology at Faculdade de Medicina de Ribeirão Preto of USP – Ribeirão Preto (SP), Brazil.

⁵Full Professor of Internal Medicine and Nutrology at Faculdade de Medicina de Ribeirão Preto of USP – Ribeirão Preto (SP), Brazil.

Conflict of interests: nothing to declare.

Submitted on: 09.19.10. Accepted on: 07.05.11.

J Vasc Bras. 2011;10(3):239-242.

The patient was placed on non-invasive ventilatory support, and a double-lumen catheter was placed on the left jugular vein for the infusion of vasoactive drugs, fluids and antibiotic therapy. Chest radiography showed pleural effusion at the right side (Figures 1 and 2). Thoracocentesis was performed at bedside and the drainage of 2,900 mL of a typical serous fluid confirmed the suspicion of hydrothorax from the TPNn infusion (Figure 3). The methylene blue test which consists in the infusion of methylene blue through the central venous catheter, with drainage of the dye through the chest tube, confirmed the diagnosis of hydrothorax (Figure 4). Fluoroscopy and chest radiography confirmed misplacement of the Port-a-Cath in the right side (Figure 5). After investigation and patient stabilization, the catheter was removed. The catheter for short-term infusion was maintained on the left jugular vein to continue the treatment that had been previously initiated to prevent a possible infection due to the patient's hemodynamic instability.

Hemothorax, a possible complication after the removal of a misplaced long-term catheter was not observed. With the discontinuation of TPN infusion in the pleural space and after chest drainage, the patient recovered well. Antibiotic therapy and ventilatory support were discontinued.

Discussion

The present paper reports a complication of central venous catheter insertion. Pneumothorax, hemorrhage, thrombosis, embolism, and vessel perforation, such as the pulmonary artery, are some of the complications reported

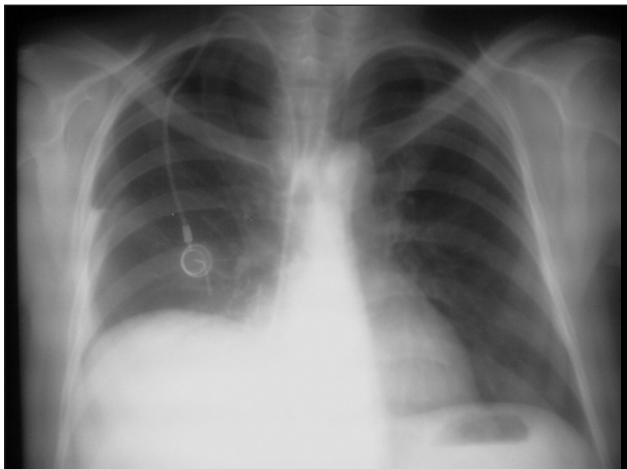


Figure 1. Chest radiography before total parenteral nutrition showing the central venous catheter at the right side, with its distal tip projected to the right atrium and right diaphragmatic cupule.

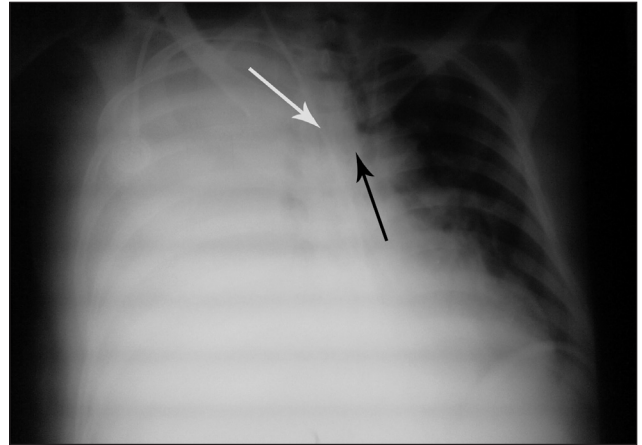


Figure 2. Chest radiography showing pleural effusion at the right side, mediastinal structures and central venous catheter (white arrow) deviated to the left; note the distal tip positioned at the right pleural cavity and the other venous catheter at the left jugular vein in adequate position (black arrow).




Figure 3. Pleural fluid obtained by toracocentesis.

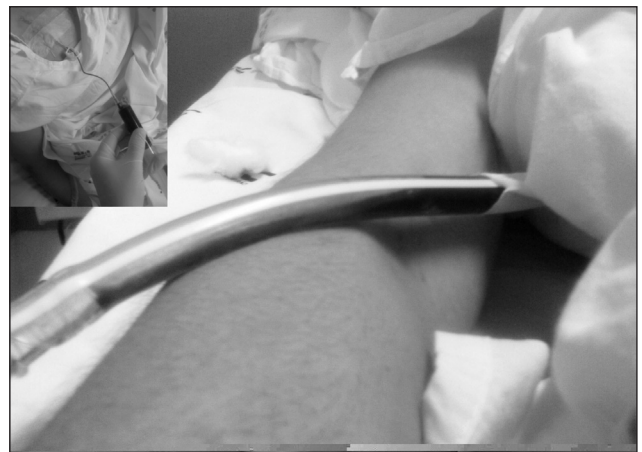

Figure 4. Infusion of methylene blue by a badly positioned catheter and drainage of the fluid.

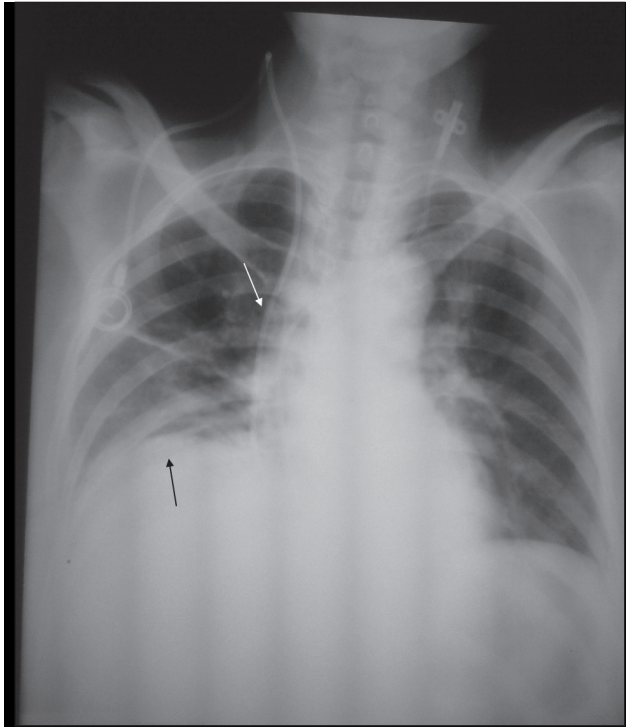


Figure 5. Chest radiography after drainage showing the drain oblique to the basis of the right hemithorax (black arrow), thickening and elevation of the catheter at the mediastinal path lateral to the right bronchus (white arrow).

in literature^{1,3-6}. In order to avoid such complications, even when the procedure is performed by a trained physician and guided by fluoroscopy, a check list for every stage of the procedure should be followed and no short cuts should be permitted. Routine aspiration of the catheter before starting the infusion is recommended, but it was not done in this case. Hydrothorax was attributed to mispositioning of the long-term catheter.

Follow-up radiographies constitute an alternative when blood flow is absent at catheter aspiration, and should be performed in two incidences (antero-posterior and lateral). Fluoroscopy, on the other hand, is the most reliable method to confirm the catheter position at the moment of insertion, as recommended by the American College of Surgeons. Although there are not data to support the routine use of radiography to prevent complications, such measures could help to determine the catheter position^{7,8}.

Anatomic landmarks have been used to estimate the adequate position of the distal tip of the catheter. For instance, the tip of catheters inserted in the subclavian or jugular vein should be positioned below the right bronchus, which corresponds to the cavo-atrial junction⁸. If

there is any doubt as to the adequate position, the catheter should not be used.

Ultrasound-guided puncture, which was not performed in the patient in this case, may shorten procedure time and decrease the chance of immediate complications⁹.

Cases of vascular erosion that result in pleural effusion have been reported as a late complication (onset up to 11 days after the insertion of the catheter) that may lead to the patient's death¹⁰. Our hypothesis is that this was the cause of hydrothorax in our patient, but we could not confirm it.

Specific treatments for hydrothorax following TPN have been little studied in literature. However, measures such as ventilatory and hemodynamic support, along with immediate suspension of TPN and chest tube drainage, were effective to prevent a bad outcome in this case. Fortunately, this event is rare, even though reported with increasing frequency, and may lead to death if not properly diagnosed and treated¹¹. We emphasize the importance of confirming catheter position before its effective use. Radiographic examination after catheter insertion and the maneuver of blood reflux into the catheter are mandatory.

References

1. Pittiruti M, Hamilton H, Biffi R, et al. ESPEN Guidelines on Parenteral Nutrition: central venous catheters (access, care, diagnosis and therapy of complications). *Clin Nutr*. 2009;28(4):365-77.
2. Haindl H, Müller H. An atraumatic needle for the puncture of ports and pumps. *Klin Wochenschr*. 1988;66(20):1006-9.
3. Lu WH, Huang TC, Pan JY, et al. A potentially fatal complication during subclavian vein catheterization in an infant with congenital heart disease-puncture to pulmonary artery directly: a case report. *J Clin Anesth*. 2008;20(3):225-7.
4. Duong MH, Jensen WA, Kirsch CM, et al. An unusual complication during central venous catheter placement. *J Clin Anesth*. 2001;13(2):131-2.
5. Lee EK. An unexpected left hydrothorax after left internal jugular venous catheterisation for total parenteral nutrition and antibiotics. *Ann Acad Med Singapore*. 2006;35(10):742-4.
6. Machado JD, Suen VM, Figueiredo JF, et al. Biofilms, infection, and parenteral nutrition therapy. *JPEN J Parenter Enteral Nutr*. 2009;33(4):397-403.
7. College's Committee on Perioperative Care. Statement on recommendations for use of real-time ultrasound guidance for placement of central venous catheters. *Bull Am Coll Surg*. 2008;93(9):35-6.
8. Askegard-Giesmann JR, Caniano DA, Kenney BD. Rare but serious complications of central line insertion. *Semin Pediatr Surg*. 2009;18(2):73-83.
9. Turker G, Kaya FN, Gurbet A, et al. Internal jugular vein cannulation: an ultrasound-guided technique versus a landmark-guided technique. *Clinics (Sao Paulo)*. 2009;64(10):989-92.

10. Duntley P, Siever J, Korwes ML, et al. Vascular erosion by central venous catheters. Clinical features and outcome. *Chest*. 1992;101(6):1633-8.
11. Westermann SA, Pahlplatz PV, Brouwers MA. Timeline of cellulitis and late development of hydrothorax induced by a right-sided central venous catheter: report of a case. *JPEN J Parenter Enteral Nutr*. 2010;34(3):341-3.

Correspondence

José Henrique Silvah
Departamento de Clínica Médica – Hospital das Clínicas
Av. Bandeirantes, 3.900, 6º andar
CEP 14048-900 - Ribeirão Preto (SP), Brazil.
E-mail: ozeenrique@gmail.com

Author's contribution

Conception and design: N/A
Analysis and interpretation: N/A
Data collection: JHS, CMML, GTA, FBC, FACN
Writing the article: JHS, CMML, GTA, FBC, FACN, SFCC, JSM
Critical revision of the article: JHS, CMML, GTA, FBC, FACN, SFCC, JSM
Final approval of the article*: JHS, CMML, GTA, FBC, FACN, SFCC, JSM
Statistical analysis: N/A

*All authors have read and approved of the final version of the article submitted to J Vasc Bras.