

The interface between images and stent grafts for the endovascular surgeon

Luiz Antonio Furuya

Some years ago, vascular surgeons started receiving in their offices a “new” type of exam, called *Multislice Tomography* or *Angiotomography*.

In the exam folder, there were tens of color images, reconstructions in several perspectives and sizes. The images were of amazing quality and beautiful, but of little use in making medical decisions. The folder also had a CD with a visualization software program and over 2000 axial images of thorax, abdomen and pelvis, with and without contrast.

Even with this vast amount of data, the images could not be manipulated, because the standard software program included was a simple image viewer, with few and limited resources. It was not possible to do any multi-planar or 3D reconstruction. The lack of a quality viewer (image post-processing software program) led to great dilemma: why request a modern, and obviously expensive, exam if it was not possible to make the best use of these data? The huge amount of information was not enough, on its own, for the exact planning, for instance, of endovascular treatment of aortic aneurysm: precise measurements and consequent selection of the best device to each patient.

Infrarenal aortic stent graft implantation is a relatively simple procedure that requires preoperative measurements of vessel length and diameter. However, the production and implantation of devices with branches to the visceral arteries is much more complex and involve several steps, including the evaluation of preoperative images, familiarity with the accesses to visceral vessels and similar skills to those required for infrarenal aortic stent graft implantation. The devices that involve visceral branches require, besides the sagittal images used in infrarenal devices, a 3D planning and multiplanar reconstruction, options not available in simple visualization software programs.

The users that did not have access to the infrastructure of a modern workstation equipped with graphic resources needed new DICOM (Digital Imaging and Communications

in Medicine) that enable them to use the data contained in these CDs of multislice computed tomography or high-field magnetic resonance.

In a few years, several DICOM viewers with better interfaces to CDs software programs were launched in the market, enabling endovascular surgeons to finally plan their cases adequately. Among the several programs available in the market, special attention will be now dedicated to iNtuition Cloud, of TeraRecon.

This software program offers several advantages when compared to other viewers. First, it is compatible with many platforms, such as Windows, Mac OS X, Android or Iphone, and many browsers, such as Internet Explorer, Mozilla and Safari, among others. Through a LAN (broadband) or 3G mobile connection, the program transforms the user's equipment into a complete workstation, with all resources, anytime and anywhere, either in the office, at home or even in the operating room, thanks to the software program technology.

TeraRecon's iNtuition Cloud offers an automatic pre-processing system (AquariusAPS), which can be activated to automatically perform several image processing stages, such as: bone removal, centerline detection, anatomy detection, parametric mapping application, pulmonary nodule detection, and not only on 3D reconstructions, but especially using multi-planar and 3D reconstructions.

TeraRecon's iNtuition Cloud uses rendering hardware called VolumePro (render board for medical images, proprietary of TeraRecon), enabling the system to use the powerful mechanism of 3D volume rendering in real time.

This technology also allows the integration of the hospital environment with the remote user, for easier access provided to multiple experts, in different places and at the same time. It means that, in actual practice, the physician can display and process images of an angiotomography performed at a hospital, with all resources of a workstation, at home

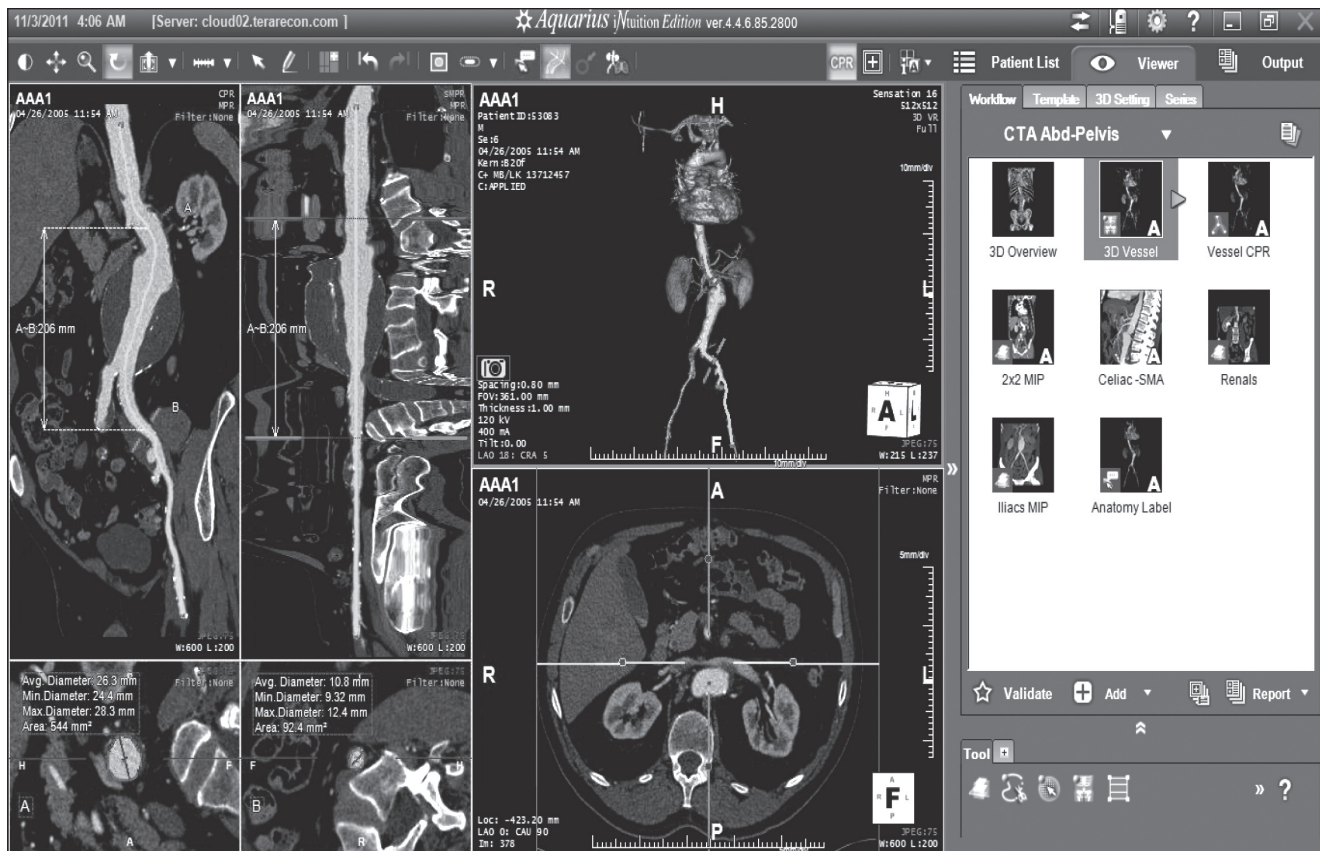


Figure 1. Opening screen of TeraRecon's iNtuition Cloud software program for abdominal angiography.

or in his office, via browser, a few minutes after the exam is completed by the tomograph or resonance equipment.

The possibility to easily access the images by a group of students and resident physicians, for instance, can expand the medical education boundaries to standards never imagined before.

As it is not a free access software program, investments are required to have access to such technology, which can be funded by an institution (hospital, university, college, etc.), a diagnostic medicine company or even an individual user (a physician, for instance), providing personalized options to each type of client.

We can say for sure that the age of caliper and negatoscope has given way to the age of mouse and high-definition displays. Precision and certainty replaced approximations

and unsupported evaluations. Much has yet to come, and the physician that gradually incorporates improvements in his clinical practice will surely discover ways to benefit from technology, generating more knowledge and higher quality in the treatment of his/her patients.

References

1. Lee WA. Endovascular abdominal aortic aneurysm sizing and case planning using the TeraRecon Aquarius workstation. *Vasc Endovascular Surg.* 2007;41(1):61-7.
2. Roy K. Greenberg, M.D. Endovascular aneurysm repair using branched or fenestrated devices [Internet]. Available from: http://www.terarecon.com/downloads/news/casestudy_greenberg_complexaneurysms.pdf.