

## CASE REPORT

---

# Endovascular treatment of renal angiomyolipoma by selective arterial embolization

## *Tratamento endovascular de angiomiolipoma renal por embolização arterial seletiva*

Renato Menezes Palácios<sup>1</sup>, Amanda Silva de Oliveira Góes<sup>1</sup>, Paloma Cals Albuquerque<sup>1</sup>,  
Maurício Figueiredo Massulo Aguiar<sup>2</sup>, Flávio Roberto Cavalleiro de Macêdo Ribeiro<sup>3</sup>,  
Adenauer Marinho de Oliveira Góes Junior<sup>4</sup>

### Abstract

We report a case of a patient with a major complaint of left lumbar pain, diagnosed with bilateral renal angiomyolipomas (AMLRs), with the most voluminous lesion of 6.2 cm in its largest diameter, underwent endovascular superselective arterial embolization with microspheres. The AMLRs are rare benign tumors. Most are sporadic, while a minority is associated with Tuberous Sclerosis Complex (ETC). The AMLRs larger than 4 cm must be treated due to higher risk of complications, especially hemorrhagic. A selective arterial embolization (EAS) is an effective and safe treatment for AMLRs.

**Keywords:** angiomyolipoma; kidney; embolization, therapeutic; microspheres.

### Resumo

Relata-se um caso de um paciente com queixa principal de dor lombar à esquerda, portador de angiomiolipomas renais (AMLRs) bilaterais, com a lesão mais volumosa de 6,2 cm em seu maior diâmetro, submetido a tratamento endovascular por embolização arterial superseletiva com microesferas. Os AMLRs são tumores benignos raros. A maioria é esporádica, enquanto uma minoria está associada à Esclerose Tuberosa Complexa (ETC). Os AMLRs maiores do que 4 cm devem ser tratados devido ao maior risco de complicações, principalmente hemorrágicas. A embolização arterial seletiva (EAS) é um tratamento efetivo e seguro para os AMLRs.

**Palavras-chave:** angiomiolipoma; rim; embolização terapêutica; microesferas.

### Introduction

---

Angiomyolipomas (AML) are rare benign tumors that account for 2% to 3% of all renal tumors<sup>1-7</sup>. They are twice more frequent among women<sup>1,5,6,8</sup>. Most are sporadic, but 10% are associated with tuberous sclerosis complex (TSC)<sup>1-7,9-11</sup>.

AML are hamartomas that contain fat, blood vessels and muscle fibers<sup>1-13</sup>.

Selective arterial embolization (SAE), an effective and safe treatment of renal angiomyolipomas (RAML),<sup>1,3,5,6,8,10,13</sup> is used in the prophylaxis of complications of high risk tumors, to contain acute hemorrhages,<sup>1,2,4,6,9,11,14,15</sup> to delay invasion of the renal parenchyma<sup>1,2,4-6,8,10,11</sup> and to reduce

bleeding during surgery as a preoperative adjuvant measure<sup>9,14,16</sup>.

The authors describe the case of a patient with bilateral RAML treated with endovascular superselective arterial embolization using microspheres.

### Case report

---

A 55-year-old man presented with a major complaint of moderate and sporadic left lumbar pain. He denied any previous hematuria. His only systemic comorbidity was controlled hypertension.

He had been followed up by a urologist for one year due to a diagnosis of multiple RAML. Because of the

---

Study carried out at the Hospital Ophir Loyola (HOL)- Belém-PA, Brazil.

<sup>1</sup> Internos do curso de medicina, (UFPA), Belém-PA, Brazil.

<sup>2</sup> Médico urologista, Belém-PA, Brazil.

<sup>3</sup> Médico cirurgião vascular, angiorradiologista e cirurgião endovascular. Belém-PA, Brazil.

<sup>4</sup> Médico cirurgião vascular, angiorradiologista e cirurgião endovascular. Professor da disciplina de habilidades médicas, curso de medicina da UFPA. Belém-PA, Brazil.

Financial support: none

Conflict of interest: nothing to declare

Submitted on: 21.02.12. Accepted on: 07.09.12.

J Vasc Bras. 2012;11(4):324-328.

greater frequency of pain and the size of the largest tumor, he was referred to an endovascular surgeon to evaluate the possibility of embolization.

A previous MRI study showed nodular lesions with an important fat component; the lesions were found in the cortex of both kidneys, five in the right and three in the left. Based on those imaging findings, a diagnosis of RAML was made. The largest lesion measured 6.2 cm in diameter and was found in the lower pole of the left kidney. In addition to RAML, MRI showed a simple renal cyst in the right kidney (Figure 1).

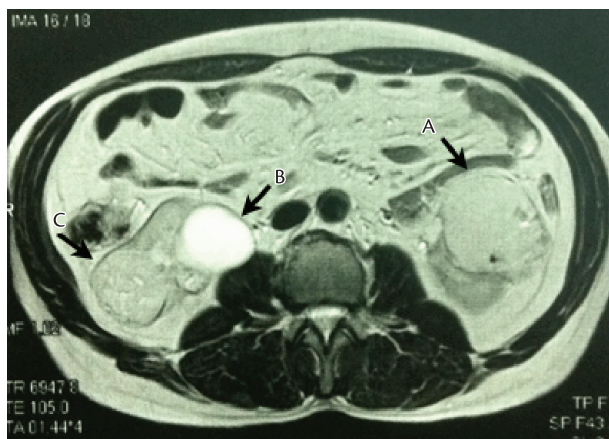
Preoperative laboratory tests were normal.

The patient underwent elective SAE for the largest RAML.

The procedure was conducted under local anesthesia and sedation. Vascular access was gained using the right common femoral artery approach, and a 5F introducer set was placed. An aortogram obtained with a 5F pigtail catheter showed that each kidney had only one artery with no significant atherosclerosis. It also showed hypervascular parenchymatous renal lesions, compatible with bilateral RAML.

A 5F Cobra 2 catheter was used for selective catheterization of the left renal artery. An angiogram showed a patent renal artery without wall irregularities or significant tortuosity (Figure 2).

Superselective catheterization of the tumor feeding vessels was performed according to a road map arteriogram and using an EmboCath® microcatheter and a Segway guidewire (BioSphere Medical) (Figure 3). One vial of 300-500-micron Embosphere® (BioSphere Medical) was used for the embolization of feeding vessels.



**Figure 1.** MRI before embolization. A: Larger angiomyolipoma in lower left kidney pole. B: Simple renal cyst in right kidney. C: Renal angiomyolipoma in right kidney.

The devascularization of the “target tumor” and the perfusion of the rest of the left kidney were confirmed by an intraoperative control angiogram (Figure 4). After the procedure was complete, manual compression was applied to the puncture site for 20 minutes.

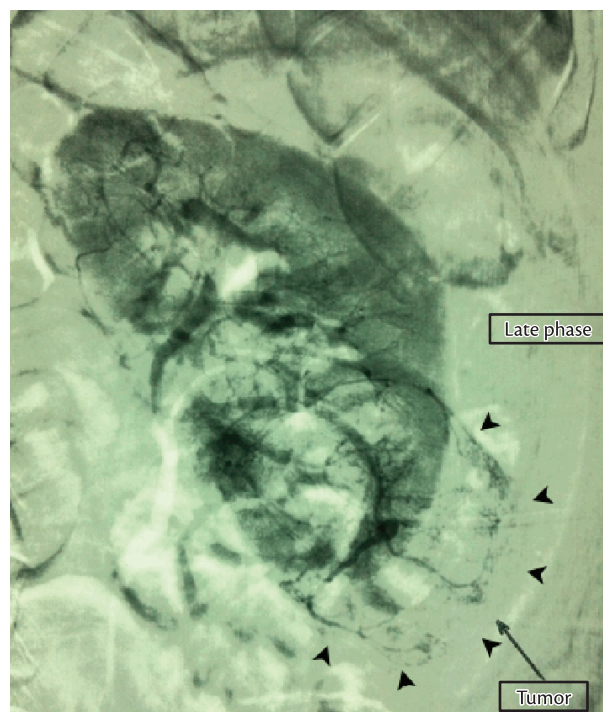
Immediately after operation, the patient had moderate left lumbar pain, successfully controlled with analgesic drugs. No vomiting, nausea or fever was observed. The patient had no other complaints or intercurrent events, and was discharged about 24 hours after the intervention.

He was referred to an urologist and returned to the endovascular surgeon’s office for evaluation on the 14<sup>th</sup> postoperative day, when he reported no complaints.

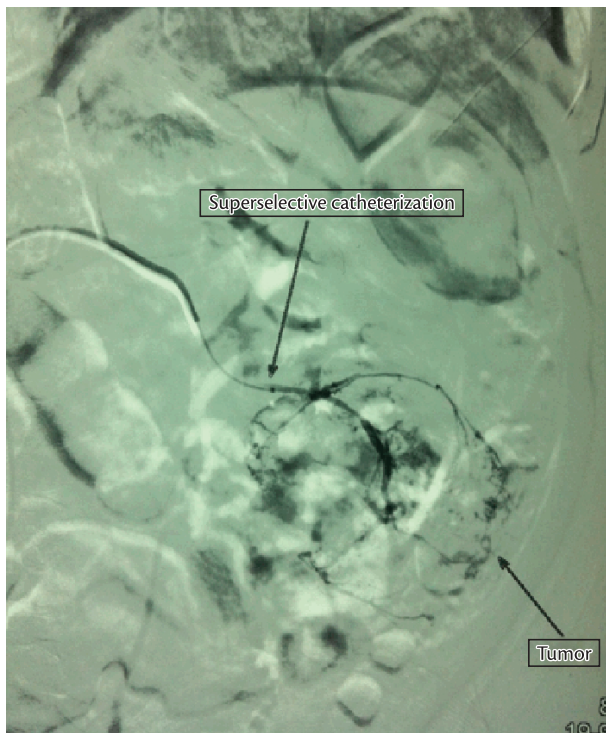
A control MRI study was performed in the third postoperative month. Results revealed a reduction of the embolized RAML to 5.8 cm. The patient is currently under regular follow-up by his urologist and has reported no other episodes of left lumbar pain.

## Discussion

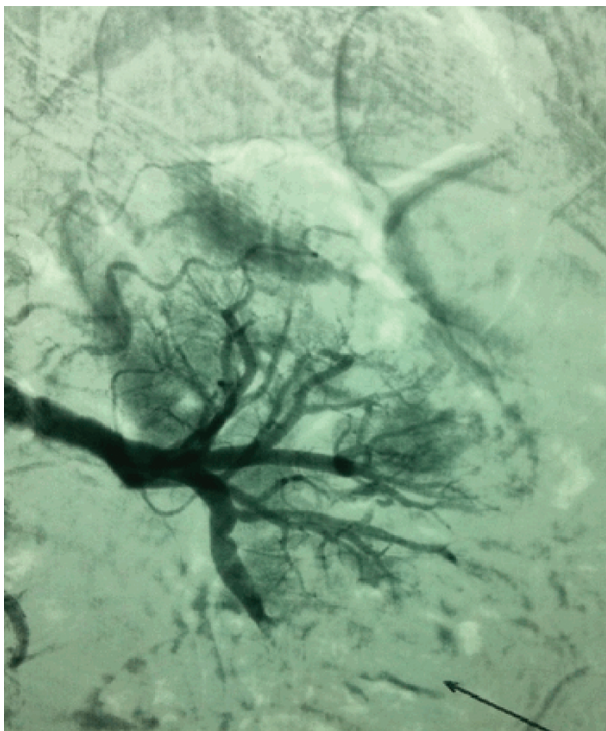
In 1951, the term “angiomyolipoma” was coined by Morgan<sup>2</sup>. Most RAML are diagnosed incidentally because 60%<sup>12</sup> are asymptomatic<sup>2,7,9,12,13</sup>. Although at an unpredictable rate,<sup>14,15</sup> tumors tend to grow<sup>6,12,14-16</sup>.



**Figure 2.** Left kidney arteriogram before embolization; late phase. Arrows point to outline of renal angiomyolipoma in lower pole.



**Figure 3.** Arteriogram obtained during superselective catheterization of tumor feeding vessels.



**Figure 4.** Left kidney arteriogram after embolization. Devascularization of embolized tumor and perfusion of remaining renal parenchyma.

There is a correlation between RAML size and the appearance of symptoms and complications<sup>1-9,14,16</sup>. The most frequent sign, in 85% of the cases, is abdominal or lumbar pain<sup>1,6,7,10,13,16</sup>. A palpable abdominal mass<sup>6,7,12</sup> is found in up to 53% of the cases,<sup>7</sup> and anemia,<sup>6,7</sup> in 21%. Retroperitoneal bleeding<sup>1-17</sup> or macroscopic hematuria<sup>1,2,6,10,11</sup> may also occur. Large tumors may affect other organs and cause anorexia<sup>1,10</sup>. Although unusual, renal parenchyma invasion may occur and lead to renal failure<sup>1-3,8,10</sup>.

Ultrasound (US),<sup>2,6</sup> CT<sup>2,6-9,11,15</sup> or MRI<sup>2,7,8,14,15</sup> studies are usually enough to establish a diagnosis and demonstrate the presence of fat inside the renal mass<sup>1,2,6,7,11</sup>. Calcifications, typical of more aggressive tumors, are rare in RAML<sup>2,13</sup>. In these cases, MRI should be used for the differential diagnosis. For renal cell carcinomas, low signal intensity is found on T1, and high signal intensity, on T2, whereas the opposite is seen in the case of fat tissues<sup>2</sup>.

When bleeding, AML should be included in the differential diagnosis of renal lesions, even if there is no evidence of intralesional fat,<sup>14</sup> as the presence of fat may be masked by tumor hemorrhage<sup>6,14,15</sup>. Its radiological aspect is typical, and a biopsy is rarely indicated<sup>2,13,14</sup>. As it is a hypervascular lesion, it may cause hemorrhage, which, however, rarely affects treatment decisions<sup>2</sup>.

Angiograms show anomalous vascularization and the formation of new vessels and microaneurysms<sup>2,4,7,9,11,15</sup>. Vessels are more susceptible to aneurysms and rupture because their walls have few normal elastic fibers,<sup>1,2,4,7,13</sup> and their muscle layer is replaced with dense fibers,<sup>2</sup> which explains why the tumor may hemorrhage easily<sup>1,2,4,6,7,11,15,17</sup>.

Of all RAML, 94% are asymptomatic,<sup>1,2,8,16</sup> and 60% bleed spontaneously<sup>8</sup>.

Tuberous sclerosis complex (TSC), described by Von Recklinghausen in 1862, is an autosomal dominant<sup>6</sup> congenital disorder whose diagnosis is made according to major and minor criteria<sup>2</sup>. Difficult-to-control seizures, mental retardation and adenoma sebaceum<sup>2,6</sup> are its three classical signs, first demonstrated by Campbell in 1905<sup>2</sup>. About 50% to 80% of the patients with TSC have RAML<sup>2,6</sup>.

Sporadic RAML is usually a single tumor. When bilateral, as in our case, TSC<sup>2</sup> should first be ruled out, which had already been done by the urologist in our case.

The criteria for intervention are: diameter greater than 4 cm (3.5 cm for some authors)<sup>1-3,5,6,8,9,10,16</sup> and pain,<sup>1,4,6,7,11,15-17</sup> as in the case described here. Other indications are active hemorrhage,<sup>1-17</sup> changes in tumor characteristics,<sup>2-4</sup> multiple RAML, bilateral or unilateral if in a single kidney,<sup>2</sup> and patients with TSC<sup>4,6</sup>.

Embolization of these lesions was described over 20 years ago<sup>4</sup> by Lalli et al.<sup>17</sup> Currently, RAML are

treated using embolization for different reasons: prevent spontaneous hemorrhage, stop active bleeding, delay progressive tumor invasion of renal parenchyma,<sup>8,14</sup> and act as a preoperative adjuvant therapy to decrease bleeding during surgery<sup>16</sup>.

The main advantage of SAE over resection is the preservation of the functional renal parenchyma<sup>2,4,5,13</sup>. In cases of active hemorrhage, its rate of success reaches 86%<sup>2</sup> and leads to gradual tumor reduction. Elective SAE prevents hemorrhage<sup>2,4,6,9,13-15</sup> in up to 94% of the cases<sup>14</sup>. Hospital stay is usually shorter than 24 hours<sup>13</sup>.

In our case, embolization was chosen because it is a minimally invasive technique whose superselective nature preserves renal function, an important consideration in the treatment of patients that may have to undergo future interventions to treat multiple tumors.

Some of the embolization agents previously described are: gelfoam,<sup>4,9,14,17</sup> polyvinyl alcohol (PVA) particles,<sup>4,8-10,13,14</sup> alcohol,<sup>9,10,14,8,13,4,5,17</sup> calibrated microspheres,<sup>4,8-10,14</sup> coils,<sup>4,8,10,11,13,14,17</sup> lipiodol<sup>5,8-10</sup> and onyx,<sup>4</sup> as well as the combined use of materials to improve the effect of embolization<sup>4,5,8,10,14,17</sup>.

Each agent has particular characteristics that define advantages and disadvantages. Alcohol, for example, penetrates to the capillary level and promotes irreversible ischemia; its low cost makes it affordable for treatment in public health care settings in developing countries, such as Brazil<sup>9</sup>. However, its embolization may be unpredictable because of its radiolucency and fluidity. Although not necessary,<sup>8,10</sup> some authors recommend the use of occlusion balloon catheters for its infusion<sup>9</sup> because they make it possible to control its dispersion in the organ that receives embolization.

Another strategy is to mix alcohol and lipiodol, because lipiodol is radiopaque and, therefore, facilitates the accurate control of the flow of material and increases the mixture's power of vascular occlusion<sup>5</sup>.

Coils should be used carefully because, once released, they block access to the most distal segments of the vessels that may have to be accessed again in early or late repeat interventions. Rupture of aneurysms in RML after embolization of distal segments have been reported and may be explained by the fact that when the vessel is occluded distally to the aneurysm, the pressure on its walls increases, which predisposes to rupture. The implantation of coils inside the aneurysm or close to it may prevent its rupture<sup>4</sup>.

One of the disadvantages of PVA is the size and shape of its irregular particles,<sup>9</sup> and special attention should be paid by the surgeon because the microcatheter may be

obstructed. The lack of particle homogeneity may also lead to inadequate penetration of the agent into the most distal points of the tumor vessels.

The calibrated microspheres are easy to handle. Their dilution in iodinated contrast medium and the use of zoom resources make it possible to control the flow of the embolization agent during injection, and, because of their regular surface and size, they rarely obstruct the microcatheter. This agent was chosen for our case because of these characteristics.

There is no consensus in the literature about the superiority of any specific embolization agent in the treatment of RAML<sup>4,8</sup>. The choice should take into consideration the surgeon's familiarity with the embolization agent and its availability in the service where the treatment will be made.

Up to 32% of all tumors treated with SAE may continue growing<sup>4,9</sup>. There is a positive association between the degree of tumor volume reduction after SAE and the percentage of fat in the RAML<sup>8</sup>.

Tumor reduction should not be used as an isolated parameter when evaluating the efficacy of embolization. Assessments should take into consideration the disappearance of symptoms,<sup>1,4,5,9,15</sup> tumor growth arrest<sup>1,4,5,9,13,15</sup> and the absence of hemorrhage<sup>4,5,9,15</sup>.

Some postoperative complications of RAML embolization are the postembolization syndrome<sup>1,2,4,9,13,15</sup> (85%),<sup>2,13</sup> renal abscess<sup>1,3,9</sup> (5%),<sup>3</sup> pleural effusion (3%)<sup>3</sup> and puncture site hematoma<sup>3,4,15</sup>. Lipiduria is a rare complication assigned to the liquefactive necrosis of tumor fat tissue<sup>8</sup>.

## Conclusions

In most cases, RAML are sporadic benign tumors. Tuberosus sclerosis complex should be ruled out when the patient has multiple and bilateral tumors.

RAML larger than 4 cm should be treated because of the higher risk of complications, particularly hemorrhage.

Studies in the literature indicate that selective arterial embolization is safe and efficacious.

## References

1. Sooriakumaran P, Gibbs P, Coughlin G, et al. Angiomyolipomata: challenges, solutions, and future prospects based on over 100 cases treated. *BJU Int.* 2009;105:101-106. <http://dx.doi.org/10.1111/j.1464-410X.2009.08649.x>
2. Cerqueira M, Xambre L, Silva V, Prisco R, Santos R. Angiomyolipoma múltiplo bilateral esporádico - caso clínico. *Acta Urol.* 2003;20(3):63-68.

3. Ozkara H, Özkan B, Solok V. Management of renal abscess formation after embolization due to renal angiomyolipomas in two cases. *Int Urol Nephrol.* 2006;38:427-429. <http://dx.doi.org/10.1007/s11255-005-0253-x>
4. Katsan K, Sabharwal T, Ahmad F, Dourado R, Adam A. Onyx embolization of sporadic angiomyolipoma. *Cardiovasc Intervent Radiol.* 2009;32:1291-1295. <http://dx.doi.org/10.1007/s00270-008-9481-7>
5. Chick C, Tan B-S, Cheng C, et al. Long-term follow-up of the treatment of renal angiomyolipomas after selective arterial embolization with alcohol. *BJU Int.* 2009;105:390-394. <http://dx.doi.org/10.1111/j.1464-410X.2009.08813.x>
6. Schneider-Monteiro ED, Lucon AM, Figueiredo AA, Rodrigues Junior AJ, Arap S. Bilateral giant renal angiomyolipoma associated with hepatic lipoma in a patient with tuberous sclerosis. *Rev Hosp Clín Fac Med S Paulo.* 2003;58(2):103-108. <http://dx.doi.org/10.1590/S0041-87812003000200008>
7. Peres L, Bader SL, Bueno AG, Espiga MC. Ruptura de Angiomiolipoma Renal Gigante. Relato de Caso. *J Bras Nefrol.* 2008;30(3):226-9.
8. Ishibashi N, Mochizuki T, Tanaka H, Okada Y, Kobayashi M, Takahashi M. A case of lipiduria after arterial embolization for renal angiomyolipomas. *Cardiovasc Intervent Radiol.* 2010;33:615-618. <http://dx.doi.org/10.1007/s00270-010-9796-z>
9. Lee S-Y, Hsu H-H, Chen Y-C, et al. Embolization of renal angiomyolipomas: short-term and long-term outcomes, complications, and tumor shrinkage. *Cardiovasc Intervent Radiol.* 2009;32:1171-1178. <http://dx.doi.org/10.1007/s00270-009-9637-0>
10. Bora A, Soni A, Sainani N, Patkar D. Emergency embolization of a bleeding renal angiomyolipoma using polyvinyl alcohol particles. *Diagn Interv Radiol.* 2007;13:213-216.
11. Katada Y, Umehara I, Ohki T, Kishino M, Shibuya H. Bilateral renal angiomyolipoma in a patient with tuberous sclerosis treated with resection of one kidney and transarterial embolization of other kidney using ct during selective arteriography: a case report. *Cases J.* 2009;2:6351. <http://dx.doi.org/10.4076/1757-1626-2-6351>
12. Lucky MA, Shingler SN, Stephenson RN. A case report of spontaneous rupture of a renal angiomyolipoma in a post-partum 21-year-old patient. *Arch Gynecol Obstet.* 2009;280:643-645. <http://dx.doi.org/10.1007/s00404-009-0964-9>
13. Faddegon S, So A. Treatment of angiomyolipoma at a tertiary care centre. The decision between surgery and angioembolization. *Can Urol Assoc J.* 2011;5(6):E138-E141. <http://dx.doi.org/10.5489/cuaj.10028>
14. Incedayi M, Turba UC, Arslan B, et al. Endovascular therapy for patients with renal angiomyolipoma presenting with retroperitoneal haemorrhage. *Eur Jvasc Endovasc Surg.* 2010;39:739e744.
15. Dabbeche C, Chaker M, Chemali R, et al. Role of Embolization in renal angiomyolipomas. *J Radiol.* 2006;87:1859-67. [http://dx.doi.org/10.1016/S0221-0363\(06\)74166-X](http://dx.doi.org/10.1016/S0221-0363(06)74166-X)
16. Shen H, Pan JH, Yan JN, et al. Resection of a giant renal angiomyolipoma in a solitary kidney with preoperative arterial embolization. *Chin Med J.* 2011;124(9):1435-1437.
17. Espinoza G, Miranda LC, Matias VAC, Fonseca JLT, Chagas VLA, Rocha FLD. Embolização pré operatória de tumores renais com micropartículas esféricas de tecnologia nacional (Spherus®-first line brasil). *Rev Col Bras Cir.* 2008;35(1). <http://dx.doi.org/10.1590/S0100-69912008000100012>

---

**Correspondence**

Adenauer Marinho de Oliveira Góes Junior  
Clínica Góes  
Rua Domingos Marreiros, 307, apto. 802 – Umarizal  
CEP 66055-210 – Belém (PA), Brazil  
Fone: (91) 8127-9656  
E-mail: adenauer-junior@ibest.com.br

**Authors' contributions**

Conception and design: AMOG, RMP, MFMA, FRCMR  
Analysis and interpretation: ASOG, PCA  
Data collection: RMP, AMOG  
Writing the article: RMP, AMOG  
Critical revision of the article: AMOG  
Final approval of the article\*: AMOG  
Statistical analysis: not applicable  
Overall responsibility: AMOG

\*All authors have read and approved the final version submitted to J Vasc Bras.