

Pulmonary embolism and stroke associated with mechanical thrombectomy

Embolia pulmonar e AVC isquêmico associado à trombectomia mecânica

Paulo Bastianetto¹, Daniel Mendes Pinto¹

Abstract

Mechanical thrombectomy offers the advantage of rapid removal of venous thrombi. It allows venous obstructions to be removed and requires shorter duration of infusion of thrombolytic agents. However, aspiration of thrombi can lead to complications, particularly pulmonary embolism and hemolysis. The validity of using vena cava filters during thrombectomy in order to avoid embolism has not yet been established. The authors report a case of massive pulmonary embolism associated with ischemic stroke in a patient with a hitherto undiagnosed patent foramen ovale. The patient developed respiratory failure and neurological deficit after thrombectomy. This case raises questions about the value of the thrombectomy for the treatment of proximal vein thrombosis due to the risks of this procedure. The authors also discuss the need for vena cava filters and ruling out a patent foramen ovale in patients undergoing thrombectomy.

Keywords: thrombectomy; mechanical thrombolysis; pulmonary embolism; stroke.

Resumo

A trombectomia mecânica tem a vantagem de levar à rápida remoção dos trombos. Permite a desobstrução venosa e a redução do tempo de infusão de trombolíticos. A aspiração dos trombos pode levar a complicações, principalmente embolia pulmonar e hemólise. Algo que não está definido é a validade do uso de filtros de veia cava durante a trombectomia, com o objetivo de evitar a TEP maciça. Os autores relatam um caso de embolia pulmonar maciça associada a AVC isquêmico, em uma paciente que apresentava forame oval patente. Não havia o diagnóstico prévio da PFO. A paciente evoluiu com insuficiência respiratória e déficit neurológico logo após a trombectomia. Neste caso, questiona-se o valor da trombectomia para o tratamento da trombose venosa proximal, devido aos riscos deste procedimento. Os autores discutem sobre a necessidade de filtro de veia cava e sobre a pesquisa de forame oval nos pacientes que serão submetidos à trombectomia.

Palavras-chave: trombectomia; trombólise mecânica; embolia pulmonar; acidente vascular cerebral.

¹ Hospital Mater Dei, Belo Horizonte, MG, Brazil.

Financial support: None.

Conflicts of interest: No conflicts of interest declared concerning the publication of this article.

Submitted: 03.29.13. Accepted: 07.29.13.

The study was carried out at Hospital Mater Dei, Belo Horizonte-MG, Brazil.

■ INTRODUCTION

The objective of early removal of thrombi after an acute deep venous thrombosis (DVT) event is to reduce the incidence of postthrombotic syndrome. The syndrome occurs in 20 to 59% of cases and is characterized by disorders caused by chronic venous hypertension, such as stasis dermatitis, dermatosclerosis and venous ulcers.^{1,2} Removal of the acute thrombi, thrombectomy, can be accomplished using conventional surgery or with percutaneous methods using catheters with a range of different mechanisms of action.

Several cases series and retrospective analyses have shown the benefits of percutaneous mechanical thrombectomy for treatment of proximal DVT.¹⁻³ However, certain risks are associated with use of this technology.

The objective of this report is to describe serious complications that occurred after a case of percutaneous thrombectomy: ischemic cerebral vascular accident (stroke) and pulmonary embolism. In addition to the description, we discuss the technique, the risks involved and results reported in the literature.

■ CASE DESCRIPTION

A female, 29-year-old patient was admitted with considerable pain and voluminous swelling of the left lower limb (LLL). The patient was taking oral contraceptives, was a non-smoker and had a family positive family history of DVT.

Doppler ultrasonography showed acute venous thrombosis in the superficial femoral, common femoral and external iliac veins of the LLL., without signs of vena cava involvement or of pulmonary embolism.

Treatment was initiated with continuous unfractionated heparin (UFH). After 2 days of treatment the symptoms remained and Doppler ultrasonography showed that the thrombotic process had progressed to the popliteal and great saphenous veins. These signs, together with the worsening edema, continual pain, increased muscle tension and cyanosis of the LLL, indicated a case of *Phlegmasia Cerulea Dolens*. Treatment with percutaneous thrombectomy and infusion of a thrombolytic agent was proposed, and accepted by the patient.

Percutaneous thrombectomy was performed 5 days after onset of symptoms, using the following technique:

- with the patient in decubitus ventral, an ultrasound-guided puncture was made in the left popliteal vein and a 6 Fr sheath fitted;

- the thrombosed segment was recanalized with a hydrophilic guide wire;
- an initial bolus of 20 mg alteplase (r-tPA) was administered via the thrombectomy catheter, using the pulse-spray technique;
- after waiting 15 min, the process of thrombi aspiration was started, using an Angiojet® device and an Xpeedior® 6F catheter. A volume of 460 mL was aspirated during a total time of use of 420 seconds, in the cranial-distal direction.

In the middle of the procedure, the patient exhibited intense dyspnea, hypoxemia, bradycardia and central and peripheral cyanosis. She was placed in decubitus dorsal and intubated. After transportation to the intensive care unit, a transthoracic echocardiogram showed considerable enlargement combined with hypocontractility of the right ventricle, and an estimated pulmonary artery pressure of 46 mmHg (normal range: up to 25 mmHg). On the basis of suspected massive pulmonary embolism, treatment was started with systemic r-tPA at a total dose of 100 mg infused over 2 hours.

Chest angiotomography confirmed pulmonary embolism with involvement of pulmonary arteries and of the inferior lobar branches bilaterally (Figure 1). The patient's brain natriuretic peptide (BNP, reached 5,296 pg/mL (normal range up to 154 pg/mL), which is associated with heart failure, poor prognosis and increased mortality in pulmonary embolism cases.

After treatment with systemic thrombolytics, on the following day the patient was extubated, respiratory parameters had improved and pulmonary artery pressure had fallen. The patient was kept anticoagulated with venous UFH .

On the third day after thrombectomy, the patient exhibited right-side hemiparesis and loss of vision, somnolence and aphasia. Magnetic resonance identified multiple areas of ischemia bilaterally, following the territory of the middle cerebral artery

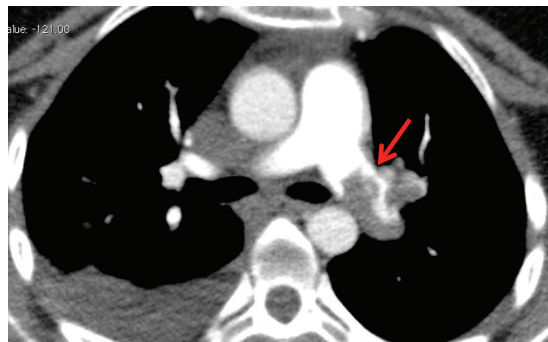


Figure 1. Angiotomography showing failure of left pulmonary artery filling (arrow).

and left posterior cerebral artery, and bilateral cerebellar infarcts (Figure 2). Treatment with UFH was withdrawn and a filter fitted in the inferior vena cava.

Transesophageal echocardiogram showed a patent foramen ovale with flow diverted from the right to the left atrium, confirming the hypothesis of ischemic stroke due to paradoxical embolism. Five days after the stroke diagnosis, the patient was discharged from intensive care, showing considerable improvement in her neurological symptoms.

After the venous thrombectomy, despite the serious complications, the swelling, pain and cyanosis of the LLL receded. Twenty-eight days after admission, the patient was discharged with a prescription for warfarin and elastic compression stockings and instructed not to take estrogens, with follow-up by the Neurology, Vascular Surgery and Physiotherapy services. A genetic study identified thrombophilia, with a heterozygous mutation of the genes for prothrombin and methylenetetrahydrofolate reductase A1298c.

Six months later the patient had returned to her usual employment and the only remaining neurological deficit was bilateral, regressive, hemianopsia.

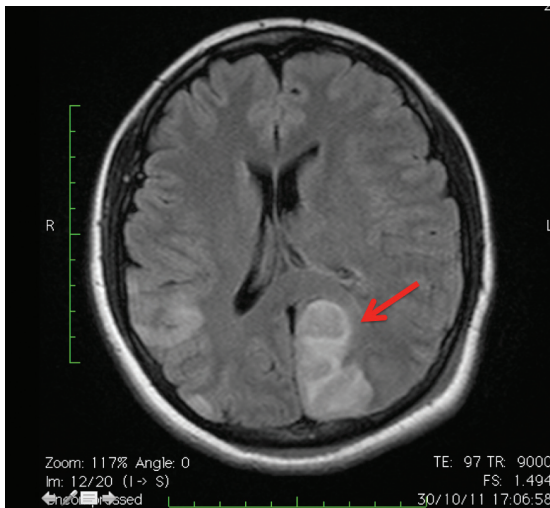


Figure 2. Magnetic Resonance showing ischemic areas on the left (arrow).

Control venous Doppler ultrasonography showed absence of deep or superficial venous reflux, with the femoropopliteal DVT in recanalization. Clinically, there was no sign of edema of the affected limb.

DISCUSSION

The proportion of iliofemoral DVT that progress to postthrombotic syndrome varies from 20 to 59%, when treated with anticoagulants alone, and from 5 to 31%, when treated using intrathrombal thrombolytics.^{2,3} When thrombolytics are used, complete thrombi removal occurs in up to 45% of cases, compared to just 4% of cases when treatment is with anticoagulation alone.^{3,4}

When compared with thrombolysis alone, mechanical thrombectomy devices offer more rapid and complete thrombus removal. Combining thrombectomy with thrombolytics offers certain advantages: shorter stays in intensive care unit and hospital; lower number of control venographies, and lower doses of the thrombolytic agent. Thrombectomy combined with thrombolytics can therefore lead to fewer hemorrhagic complications and reduced morbidity (Table 1).^{5,6}

Several different thrombectomy devices are available on the market, with a range of different mechanisms of action: simple aspiration of thrombi, hydrodynamic (aspiration by negative pressure of saline jets), fragmentation and combination systems.⁷

The device used in this case, the Angiojet® (Possis Medical Inc., Minneapolis, MN), has an action based on the Venturi effect. The catheter employed, an Expeedior®, has two lumens: one for infusion of saline and the other for aspiration of the fluid and the clot. A high-pressure jet of saline solution is directed from the tip of the catheter backwards, thereby creating a vacuum effect, which forces the clot to enter the catheter after maceration. The catheter does not touch the vessel wall and the high-pressure jet does not denude the endothelium, thereby preserving its antithrombotic effect.

The main complications related to mechanical thrombectomy are hemolysis and pulmonary embolization. Hemolysis is the result of fragmentation of red blood cells caused by contact with saline jets.

Table 1. Indications for percutaneous thrombectomy.⁶

Indication	Grade of recommendation and level of evidence
First episode of acute iliofemoral DVT, up to 14 days since onset of symptoms, low risk of bleeding, good functional capacity and an acceptable life expectancy.	2C
Patients with iliofemoral DVT, associated or not with femoropopliteal thrombosis, threatening limb viability (<i>phlegmasia cerulea dolens</i>)	1A

Almost all patients exhibit hemoglobinuria.^{8,9} Venous hydration is essential, with the objective of avoiding kidney damage. Our patient did not suffer from significant hemolysis.

Several different studies have found evidence of asymptomatic pulmonary embolism at rates of 5.3% to 17%, in addition to a few symptomatic cases.¹⁰⁻¹³ The vena cava filter prevents embolization by larger thrombi, but does not restrict the passage of microthrombi into pulmonary circulation. As a result, the benefit of using a cava filter in patients undergoing aspiration thrombectomy is not well-established in the literature. Certain groups may benefit from protection with a filter, such as patients with little cardiopulmonary reserves or where the thrombus extends to the vena cava.¹⁴

Patients with a persistent foramen ovale are at greater than normal risk from venous thrombosis because of the possibility of paradoxical embolism. The foramen ovale can remain patent in 25% of the population. Diagnosis is made by transesophageal echocardiogram. In many cases the foramen initially closes, only to open in situations of right ventricle overload.¹⁵ In the case described here, the extensive cerebral vascular accident was associated with the patent foramen ovale. The increased pressure in the pulmonary artery could have diverted the clots to the left atrium with consequent cerebral embolization. Such a mechanism could explain the fact that cerebral ischemia only had onset on the third day after the pulmonary embolism.

After our experience with this case, and in view of the high prevalence of persistent foramen oval in the population, we now use transesophageal echocardiograms to examine all patients who are to undergo thrombectomy.

Mechanical thrombectomy and infusion of thrombolytics are effective options for removing obstruction from the iliac veins and reducing incidence of the postthrombotic syndrome. They are considered safe procedures. The majority of complications reported in the literature are primarily related to hemolysis or pulmonary embolism with little symptomology. However, this report illustrates a case of massive pulmonary embolism and ischemic stroke, which are potentially lethal complications, associated with a technique considered to be appropriate. If the safety of thrombectomy is to be increased, protocols are needed for profiling patients and answering questions such as the volume of thrombi to be aspirated, the duration of thrombi aspiration and the duration of thrombolytic infusion,

in addition to defining indications for use of a vena cava filter for protection.

REFERENCES

- Nazir SA, Ganeshan A, Nazir S, Uberoi R. Endovascular treatment options in the management of lower limb deep venous thrombosis. *Cardiovasc Intervent Radiol.* 2009;32(5):861-76. PMID:19641957. <http://dx.doi.org/10.1007/s00270-009-9662-z>
- Gloviczki P, Comerota AJ, Dalsing MC, et al. The care of patients with varicose veins and associated chronic venous diseases: clinical practice guidelines of the Society for Vascular Surgery and the American Venous Forum. *J Vasc Surg.* 2011;53(5):25-48S. PMID:21536172. <http://dx.doi.org/10.1016/j.jvs.2011.01.079>
- Comerota AJ, Gravett MH. Iliofemoral venous thrombosis. *J Vasc Surg.* 2007;46(5):1065-76. PMID:17980295. <http://dx.doi.org/10.1016/j.jvs.2007.06.021>
- Malgor RD, Gasparis AP. Pharmaco-mechanical thrombectomy for early thrombus removal. *Phlebology.* 2012;27(Suppl 1):155-62. PMID:22312084. <http://dx.doi.org/10.1258/phleb.2012.012514>
- Bush RL, Lin PH, Bates JT, Mureebe L, Zhou W, Lumsden AB. Pharmacomechanical thrombectomy for treatment of symptomatic lower extremity deep venous thrombosis: safety and feasibility study. *J Vasc Surg.* 2004;40(5):965-70. PMID:15557912. <http://dx.doi.org/10.1016/j.jvs.2004.08.025>
- Meissner MH, Gloviczki P, Comerota AJ, et al. Early thrombus removal strategies for acute deep venous thrombosis: Clinical Practice Guidelines of the Society for Vascular Surgery and the American Venous Forum. *J Vasc Surg.* 2012;55(5):1449-62. PMID:22469503. <http://dx.doi.org/10.1016/j.jvs.2011.12.081>
- Kim HS, Patra A, Paxton BE, Khan J, Streiff MB. Adjunctive percutaneous mechanical thrombectomy for lower-extremity deep vein thrombosis: clinical and economic outcomes. *J Vasc Interv Radiol.* 2006;17(7):1099-104. PMID:16868161. <http://dx.doi.org/10.1097/01.RVI.0000228334.47073.C4>
- Biuckians A, Meier GH. Treatment of symptomatic lower extremity acute deep venous thrombosis: role of mechanical thrombectomy. *Vascular.* 2007;15(5):297-303. <http://dx.doi.org/10.2310/6670.2007.00070>
- Cynamon J, Stein EG, Dym RJ, Jagust MB, Binkert CA, Baum RA. A new method for aggressive management of deep vein thrombosis: retrospective study of the power pulse technique. *J Vasc Interv Radiol.* 2006;17(6):1043-9. PMID:16778240. <http://dx.doi.org/10.1097/01.RVI.0000221085.25333.40>
- Kasirajan K, Gray B, Ouriel K. Percutaneous AngioJet thrombectomy in the management of extensive deep venous thrombosis. *J Vasc Interv Radiol.* 2001;12(2):179-85. [http://dx.doi.org/10.1016/S1051-0443\(07\)61823-5](http://dx.doi.org/10.1016/S1051-0443(07)61823-5)
- Lin PH, Zhou W, Dardik A, et al. Catheter-direct thrombolysis versus pharmacomechanical thrombectomy for treatment of symptomatic lower extremity deep venous thrombosis. *Am J Surg.* 2006;192(6):782-8. PMID:17161094. <http://dx.doi.org/10.1016/j.amjsurg.2006.08.045>
- Vedantham S, Thorpe PE, Cardella JF, et al. Quality improvement guidelines for the treatment of lower extremity deep vein thrombosis with use of endovascular thrombus removal. *J Vasc Interv Radiol.* 2006;17(3):435-47. PMID:16567668. <http://dx.doi.org/10.1097/01.RVI.0000197348.57762.15>
- Augustinos P, Ouriel K. Invasive approaches to treatment of venous thromboembolism. *Circulation.* 2004;110(Suppl 1):I27-34. PMID:15339878. <http://dx.doi.org/10.1161/01.CIR.0000140900.64198.f4>

14. Kölbel T, Alhadad A, Acosta S, Lindh M, Ivancev K, Gottsäter A. Thrombus embolization into IVC filters during catheter-directed thrombolysis for proximal deep venous thrombosis. *J Endovasc Ther.* 2008;15(5):605-13. PMID:18840047. <http://dx.doi.org/10.1583/08-2462.1>
15. Chamié F, Chamié D, Ramos S, et al. Fechamento Percutâneo do Forame Oval Patente. *Rev Bras Cardiol Invas.* 2005;13(3):185-19.

Correspondence

Paulo Bastianetto
Rua Uberaba, 436, sala 502 - Barro Preto
CEP 30180-080 - Belo Horizonte (MG), Brazil
Tel.: +55 (31) 32952030
E-mail: paulobastianetto@gmail.com

Author information

PB é Angiologista e Cirurgião Vascular / Endovascular, Membro Efetivo da SBACV, Hospital Mater Dei e Angiocare.
DMP é Angiologista e Cirurgião Vascular, Membro Titular da SBACV, Hospital Mater Dei e Instituto Vascular BH.

Author contributions

Conception and design: PB, DMP
Analysis and interpretation: PB, DMP
Data collection: PB
Writing the article: PB, DMP
Critical revision of the article: PB, DMP
Final approval of the article*: PB, DMP
Statistical analysis: N/A

* All authors have read and approved of the final version of the article submitted to *J Vasc Bras.*