

# Endovascular treatment of iatrogenic penetrating trauma of the carotid artery: case report

## *Tratamento endovascular de trauma penetrante iatrogênico de artéria carótida: relato de caso*

Eduardo Lichtenfels<sup>1,2</sup>, Marco Aurelio Cardozo<sup>2</sup>, Nilon Erling Jr.<sup>1,2</sup>, Newton Roesch Aerts<sup>1,2</sup>

### Abstract

Carotid trauma demands early diagnosis and treatment. Open repair may be technically challenging if the trauma is at the base of the neck. We present a case of iatrogenic penetrating carotid trauma caused by insertion of a hemodialysis catheter. Treatment was accomplished by placement of a covered stent-graft in the common carotid artery, covering the puncture site. This case suggests that placement of a covered stent-graft is a good option for treatment of iatrogenic injury to the carotid artery.

**Keywords:** carotid artery; covered stent graft; carotid perforation; carotid blowout.

### Resumo

O trauma da carótida exige diagnóstico e tratamento precoces. O tratamento convencional pode ser tecnicamente desafiador se o trauma penetrante for na base do pescoço. Apresentamos um caso de trauma penetrante da carótida associado ao implante iatrogênico de um cateter para hemodiálise. O tratamento foi realizado através da colocação de uma endoprótese na artéria carótida comum, cobrindo o local da punção. Este caso sugere que a colocação de uma endoprótese é uma boa opção para o tratamento de lesão iatrogênica da artéria carótida.

**Palavras-chave:** artéria carótida; endoprótese; perfuração carotídea; ruptura carotídea.

<sup>1</sup> Universidade Federal de Ciências da Saúde de Porto Alegre – UFCSPA, Departamento de Cirurgia, Porto Alegre, RS, Brazil.

<sup>2</sup> Irmandade Santa Casa de Misericórdia de Porto Alegre – ISCMPA, Serviço de Cirurgia Vascular e Endovascular, Porto Alegre, RS, Brazil.

Financial support: None.

Conflicts of interest: No conflicts of interest declared concerning the publication of this article.

Submitted: 01.25.14. Accepted: 03.26.14.

The study was carried out at the Department of Surgery, Discipline of Angiology and Vascular Surgery of UFCSPA, and at the Service of Vascular and Endovascular Surgery of ISCMPA.

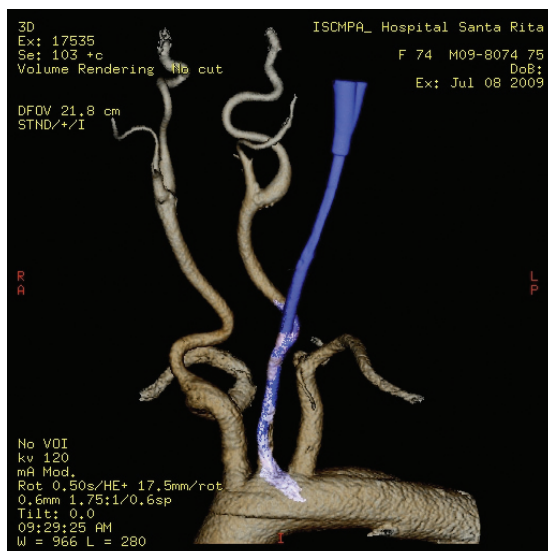
## INTRODUCTION

Arterial traumatism involving the cervical region have a low incidence, but elevated morbidity and mortality. Despite advances in diagnostic and surgical techniques, carotid injuries at the base of the neck are still challenging for vascular and trauma surgeons.<sup>1,2</sup> Iatrogenic penetrating traumas of the carotid artery are very rare, but have been described in the literature.<sup>3-5</sup> The conventional approach to treating these cases is with open surgery. However, as endovascular techniques have evolved, percutaneous treatment is becoming a lower morbidity and mortality option for treatment of this type of complication.

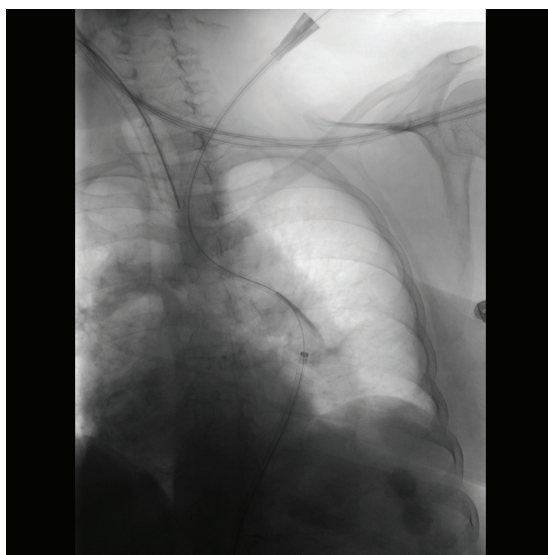## CASE DESCRIPTION

The patient was a 75-year-old female with chronic renal failure who was on hemodialysis but with difficult vascular access. On the day she was admitted, a catheter for hemodialysis was placed in the femoral vein, without intercurrent conditions. On the day after admission, the Nephrology team attempted to place a catheter in the left jugular vein for hemodialysis, which was inadvertently placed into the left common carotid artery. The catheter was left in the carotid, the patient was heparinized and the Vascular and Endovascular Surgery Team was called. A cervical angiogram showed the catheter placed in the common carotid artery at the junction between its proximal and mid thirds and with the tip in the ascending aorta (Figure 1).

The decision was taken to attempt endovascular correction of the carotid trauma and to remove the hemodialysis catheter manually. The right common femoral artery was dissected and a 9 French wired introducer sheath was advanced up to the thoracic aorta. A 0.035" × 450 cm jagwire guide-wire (Boston, Natick, MA, USA) was inserted via the hemodialysis catheter, the guide-wire was captured using a GooseNeck snare (EV3, Plymouth, MN, USA) and removed via the common femoral (Figure 2). The 9F introducer sheath was repositioned in the left common carotid artery. Angiography was used to identify the perforation site and the carotid bifurcation. A Viabahn 8 mm × 5 cm endoprosthesis (Gore, Flagstaff, AZ, USA) was positioned at the site of the orifice, the hemodialysis catheter was removed manually and the endoprosthesis released and then post-dilatation was performed using a 7 × 40 mm balloon catheter. Control angiography demonstrated patency of the treated segment with no leakage (Figure 3).



**Figure 1.** Preoperative angiogram showing the hemodialysis catheter in the left common carotid artery.

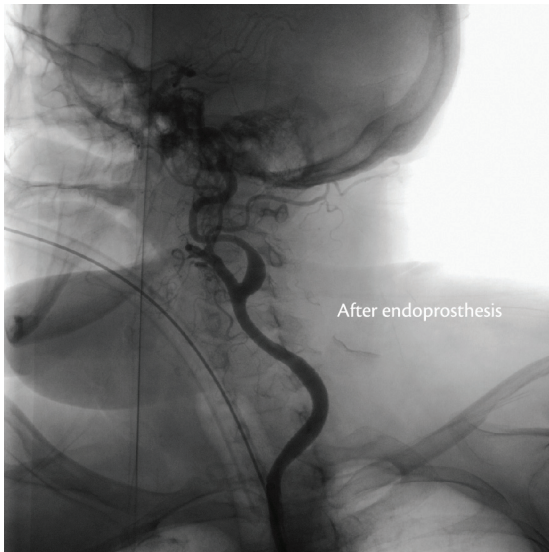

**Figure 2.** Fluoroscopy showing the hemodialysis catheter, the guide-wire and the 9 French long introducer sheath.

Later, the patient had a peritoneal dialysis catheter implanted without intercurrent conditions and was discharged in good clinical conditions.

## DISCUSSION

The standard treatment for a perforating trauma of an artery is ligation with permanent occlusion of the artery. This technique is traditionally employed in cases of carotid rupture, particularly in cases in which there is insufficient time to evaluate collateral cerebral circulation, and endovascular or surgical



**Figure 3.** Control angiography showing final appearance after release of the endoprosthesis in the left common carotid artery.

occlusion of both carotid and the rupture site are performed.<sup>4,6</sup> Vascular ligation or occlusion involves a very high risk of ischemic cerebral events.<sup>4,6,7</sup> Surgical management should therefore prefer reconstructive techniques or those that preserve cerebral flow, whenever the patient's condition allows.<sup>3</sup> In our case, the patient had suffered a perforating carotid trauma that was sealed by the hemodialysis catheter itself, which had not been removed from the placement site (Figure 1). This meant that it was possible to conduct preoperative imaging exams and plan the most appropriate and safest technique for correction of the perforation. In order to avoid embolic complications caused by the large-caliber intra-arterial catheter, the patient was kept on heparin until the catheter had been removed and the endovascular repair accomplished.

Endovascular repair of the perforating carotid trauma was the option chosen in the case described here because of the age of the patient, 75 years, the presence of multiple comorbidities and the elevated surgical risk, and also because of the perforation site, which was located at the base of the neck and involved the proximal segment of the common carotid. It is known that carotid injuries involving the base of the neck are a challenge for surgeons.<sup>1,2</sup> The endovascular technique is a less invasive option, offering lower morbidity and mortality for treatment of carotid traumas and allowing preservation of the common carotid artery and cerebral flow, with the

added advantage that it demands less time in surgery than conventional procedures.<sup>7-10</sup>

In the literature we found reports of carotid traumas treated with a wide variety of endoprostheses, both self-expanding and balloon-expanded.<sup>6-9,11,12</sup> In the case described here, a self-expanding Viabahn endoprosthesis was used because of its flexibility, since the patient had a tortuous carotid, and because of the simple and rapid release mechanism, which was important because of the need to release it at the same moment that the catheter was removed manually. An 8 × 50 mm endoprosthesis was used in a 7 mm target artery, making correct placement possible and preventing leakage or migration. The long introducer sheath was used to protect the material as it was advanced to the placement site and to provide angiographic control. The hemodialysis catheter (intra-arterial) itself was used to advance the guide-wire and perform the through-and-through technique, for passage and positioning of the sheath in the proximal common carotid. A carotid filter was not used because of incompatibility between the filter guide-wire (0.014") and the wire needed to place the endoprosthesis (0.035"). The nature of the injury, which was traumatic and not atherothrombotic, meant that a filter was not absolutely necessary.

The case described here suggests that use of the endovascular technique, with endoprosthesis placement, is a good option for treatment of cases of iatrogenic perforating carotid trauma.

## REFERENCES

1. Marine L, Sarac TP. Hybrid stent-graft repair of an iatrogenic complex proximal right common carotid artery injury. *Ann Vasc Surg.* 2012;26:574.e1-7.
2. Dos Santos Junior EP, Batista RRAM, De Oliveira MB, Alves RF, Blois RR. Pseudoaneurisma de carótida comum secundário à trauma contuso: opção de tratamento por cirurgia a céu aberto. *J Vasc Br.* 2011;10:261-5.
3. Agid R, Simons M, Casaubon LK, Sniderman K. Salvage of the carotid artery with covered stent after perforation with dialysis sheath. A case report. *Interv Neuroradiol.* 2012;18:386-90. PMID:23217633 PMCID:PMC3520552.
4. Luo CB, Chang FC, Teng MM, Chen CC, Lirng JF, Chang CY. Endovascular treatment of the carotid artery rupture with massive hemorrhage. *J Chin Med Assoc.* 2003;66:140-7. PMID:12779033.
5. Thakore N, Abbas S, Vanniasingham P. Delayed rupture of common carotid artery following rugby tackle injury: a case report. *World J Emerg Surg.* 2008;2:14. PMID:18355416 PMCID:PMC2277436. <http://dx.doi.org/10.1186/1749-7922-3-14>
6. Wan WS, Lai V, Lau HY, Wong YC, Poon WL, Tan CB. Endovascular treatment paradigm of carotid blowout syndrome: review of 8-years experience. *Eur J Radiol.* 2013;82:95-9. PMID:21310571. <http://dx.doi.org/10.1016/j.ejrad.2011.01.061>
7. Lesley WS, Chaloupka JC, Weigle JB, Mangla S, Dogar MA. Preliminary experience with endovascular reconstruction

- for the management of carotid blowout syndrome. *Am J Neuroradiol.* 2003;24:975-81. PMID:12748106s.
8. Pampana E, Gandini R, Stefanini M, et al. Coronaric stent-graft deployment in the treatment of carotid blowout. *Interv. Neuroradiol.* 2011;17:490-4. PMID:22192556 PMCID:PMC3296512.
  9. Chang FC, Lirng JF, Luo CB, et al. Carotid blowout syndrome in patients with head and neck cancers: re-constructive management by self-expandable stent- grafts. *Am J Neuroradiol.* 2007;28:181-8. PMID:17213454.
  10. Segal DH, Sen C, Bederson JB, et al. Predictive value of balloon test occlusion of the internal carotid artery. *Skull Base Surg.* 1995;5:97-107. PMID:17171183 PMCID:PMC1661829. <http://dx.doi.org/10.1055/s-2008-1058940>
  11. McGettigan B, Parkes W, Gonsalves C, Eschelmann D, Keane W, Boon MS. The use of a covered stent in carotid blowout syndrome. *Ear Nose Throat J.* 2011;90:E17. PMID:21500155.
  12. Chen YL, Wong HF, Ku YK, Wong AM, Wai YY, Ng SH. Endovascular covered stent reconstruction improved the outcomes of acute carotid blowout syndrome. Experience at a single institute. *Interv. Neuroradiol.* 2008;14:23-27. PMID:20557797 PMCID:PMC3328068.

---

#### Correspondence

Eduardo Lichtenfels  
Rua Ramiro Barcelos, 910/1002  
CEP 90570-030 - Porto Alegre (RS), Brazil  
E-mail: elichtenfels@gmail.com

#### Author information

EL é Professor Adjunto de Angiologia e Cirurgia Vasculard da Universidade Federal de Ciências da Saúde de Porto Alegre (UFCSA), Cirurgião do Serviço de Cirurgia Vasculard e Endovascular da Irmandade Santa Casa de Misericórdia de Porto Alegre (ISCMPA), Mestre e Doutor em Medicina pela UFCSA.  
MAC é Cirurgião do Serviço de Cirurgia Vasculard e Endovascular da ISCMPA e Mestre em Cirurgia pela Fundação Faculdade Federal de Ciências Médicas de Porto Alegre (FFCMPA).  
NEJ é Professor Adjunto de Angiologia e Cirurgia Vasculard da UFCSA, Doutor em Cirurgia Cardiovascular pela Universidade Federal de São Paulo (Unifesp) e Cirurgião do Serviço de Cirurgia Vasculard e Endovascular da ISCMPA.  
NRA é Professor Adjunto de Angiologia e Cirurgia Vasculard da UFCSA, Professor Livre-Docente pela Unifesp e Chefe do Serviço de Cirurgia Vasculard e Endovascular da ISCMPA.

#### Author contributions

Conception and design: EL, MAC, NEJ, NRA  
Analysis and interpretation: EL  
Data collection: EL, MAC  
Writing the article: EL  
Critical revision of the article: EL, MAC, NEJ, NRA  
Final approval of the article\*: EL, MAC, NEJ, NRA  
Statistical analysis: N/A  
Overall responsibility: EL  
Obtained funding: None.

\* All authors have read and approved of the final version of the article submitted to *J Vasc Bras.*